

Original Article	Anatomical Variations of the Proximal Segment of Middle Cerebral Artery and their Clinical Significance: Three Dimensional Magnetic Resonance Angiography study in Egyptians <i>Walaa Mohamed Sayed, Sherif Fahmy Arsanyos, Mohamed Hafiz Shabaan</i> <i>Department of Anatomy and Embryology, Faculty of Medicine, Kasr Al-Ainy, Cairo University, Cairo, Egypt.</i>
-------------------------	--

ABSTRACT

Background: Neurosurgical intervention and endovascular manipulation of middle cerebral artery (MCA) needs more information about the anatomy of its different segments specially its proximal one.

Aim of the work: Is to assess different morphological and morphometric measurements of the proximal segment (M1) of MCA in Egyptians. Also, is to evaluate clinical significance of such variations.

Material and Methods: This research was carried out retrospectively on three dimensional magnetic resonance angiography images of eighty healthy individuals without any cerebrovascular abnormalities. The morphological variations as well as measurements (the lengths and diameters) of M1 were evaluated. Side and sex differences as well as correlation between different parameters were also done.

Results: There was only statistically significant sex difference regarding M1 length on right side. In addition, there was significant positive correlation between different measurements of M1 of MCA regarding side. M1 branches were mostly bipode and least quadripode on both sides. The division of M1 was observed more frequent distal to genu and less frequent proximal to genu on both sides. At transverse plane, high percentage of concave posterior course of M1 was seen in 52.5% and 55% of cases on right and left sides, respectively. While concave anterior course of M1 was least noticed in 13.8% and 10% on right and left sides, respectively. Early cortical artery (ECA) was found in 65 % of studied cases.

Conclusion: The anatomical variations results of M1 of MCA as evaluated by 3D-MRA are very useful for neurosurgical approach.

Received: 9 December 2019, **Accepted:** 16 January 2020

Key Words: Anatomical variations, angiography, middle cerebral artery, MRA, proximal segment.

Corresponding Author: Walaa Mohamed Sayed, MD, Department of Anatomy and Embryology, Faculty of Medicine, Cairo University, Cairo, Egypt. **Tel.:** 01093853727, **E-mail:** walaa_sayed@hotmail.com

The Egyptian Journal of Anatomy, ISSN: 0013-2446, Vol. 43 No. 2

INTRODUCTION

Middle cerebral artery (MCA) is the larger of the two terminal branches of internal carotid artery (ICA); MCA is also considered as the actual continuation of ICA^[1,2].

Different cerebral lobes affects the embryological development of MCA, the latter arises from the arteries located on the superolateral surface of the cerebral hemisphere that forming the insula before infolding. During 8–12 weeks' gestation, these cortical vessels originate from end segment of ICA. When insula develops, the arteries pierce the developed lateral fissure and during this gestational duration, they form MCA that its development progresses to birth^[3].

Knowing the variations of the anatomical structure and measurements of MCA is essentially important for several studies^[1,4,5]. Moreover, due to high frequency of vascular abnormalities of MCA, neurosurgical intervention and endovascular manipulation of the MCA needs more information about the anatomy of its different segments specially its proximal one^[6,7]. Additionally, increasing the incidence of the intracranial aneurysms particularly of MCA which is considered the commonest site of aneurysm following the anterior communicating artery enhances the interest of the researches on the anatomical variations of the MCA^[8,9]. Moreover, management of stroke by removal of the thrombus interventionally requires sufficient knowledge about the anatomical variations of

DOI: 10.21608/EJANA.2020.18364.1054

MCA as it is one of the most common sites of thrombi formation^[7].

Dissection of the human brains gave a chance to study the different anatomical features of MCA and its proximal segment (M1)^[1]. However, magnetic resonance imaging added more to the field of description and evaluation of the anatomical variations of the arteries located inside the cranial cavity. In particular, three dimensional magnetic resonance angiography (3D-MRA) which is a highly sensitive, non-invasive technique that gives an easy way for In vivo visualization of the intracranial arteries^[10]. As a result of high reliability of magnetic resonance angiography (MRA) outcomes, it is used for diagnostic and therapeutic studies of cerebral arteries^[6]. Little literature discussed the variations in the anatomical structure and measurements of the proximal segment of middle cerebral artery in normal individuals using 3D-MRA.

The present work was performed to assess the anatomical morphological and morphometric variations of the proximal segment of middle cerebral artery by retrospective analysis of the three dimensional magnetic resonance angiographs. Side, sex differences and correlation between the different measurements, frequencies of the morphological parameters as well as comparison with other populations for evaluation of the racial anatomical variations were done. The findings were aimed to help the neurosurgical scientists with some guidelines important in their approach to middle cerebral artery.

MATERIAL AND METHODS

A. Patients:

This work was done retrospectively on Magnetic Resonance Angiography (MRA) images of the cerebral vessels of eighty cases (22 females, 58 males) with the range of age between 21-55 years old. MRA images were obtained from Nile scan Center, Cairo, Egypt. These MRA images were used to examine the anatomical morphological and morphometric variations of the proximal segment of middle cerebral artery.

Inclusion criteria: Individuals with healthy angiographic examination admitted to hospital

with headache and vertigo were included in the current work. Consents were obtained from the patients to use their MRA images.

Exclusion criteria: Patients with stroke, vascular malformations, and aneurysm in one or more of the intracranial vessels or any cerebrovascular disease were excluded from the present study.

B. Three Dimensional Magnetic Resonance Angiography (3D-MRA) technique:

Magnetic resonance investigation was done by using three dimensional time of flight magnetic resonance angiography (3D-TOF MRA). The technique of MRA included non-contrast 3D-TOF transaxial acquisition that was done for assessment of all persons with TR/TE/FA (30–40/6–10ms/20–25). Rectangular field of view (FOV) 150 x 200 mm, matrix size 192 x 256 with slice thickness of 0.8–1 mm and 96 partitions with the total imaged volume (effective slab thickness) 72mm. The post-processing algorithm, maximum intensity projection (MIP) was used to produce angiographic-like images at 15 increments generating 12 MIP projections.

The images of MRA were evaluated independently by two anatomical scientists and one double qualified radiologist and anatomist to localize the major morphological anatomical characteristics of the proximal segment of MCA.

C. Morphological and morphometric anatomical parameters of the proximal segment (M1) of middle cerebral artery (MCA)^[11]:

- **Definition of M1 of MCA (Fig. I):** it is the part of the middle cerebral artery (MCA) that is located between the internal carotid artery (ICA) bifurcation and the MCA genu at the site of MCA bending sharply upwards and backwards.

- **The following morphological and morphometric parameters of M1 of MCA were evaluated:**

1. **The length of M1 of MCA (Fig. II):** was measured by moving the cursor inside the artery and continue on the different curves to obtain the most reliable length.

2. The caliber (diameter) of M1 of MCA (Fig. III): was measured by placing the cursor on the outer aspects of the middle part of the artery and the external caliber was assessed.

3. The number of divisions (branches) of MCA: were classified as monopode, bipode, tripod or quadripode.

4. The site of division (branching pattern): was evaluated as; before the genu, at genu or after the genu.

5. The determination of number of early cortical branch (ECB): is known as narrow arteries that always originate mostly at right angle from the proximal segment moving to the cerebral cortex.

D. Statistical analysis^{[12]:}

The obtained data were statistically analyzed using IBM SPSS version 21 (SPSS Inc., Chicago, IL) for the following:

1. Numerical data (M1 length and diameter), was expressed as mean \pm SD. To study the side and sex differences of the variable measurements, paired t test was done and statistical difference was significant when $p \leq 0.05$.

2. Correlation using Pearson's correlation test between the mean length and diameter. Level of significance at p value < 0.05 and highly significant with p value < 0.01 .

3. Chi square test was applied to know the frequencies of the morphological parameters (division pattern of M1, site of M1 division and number of the present early cortical branch).

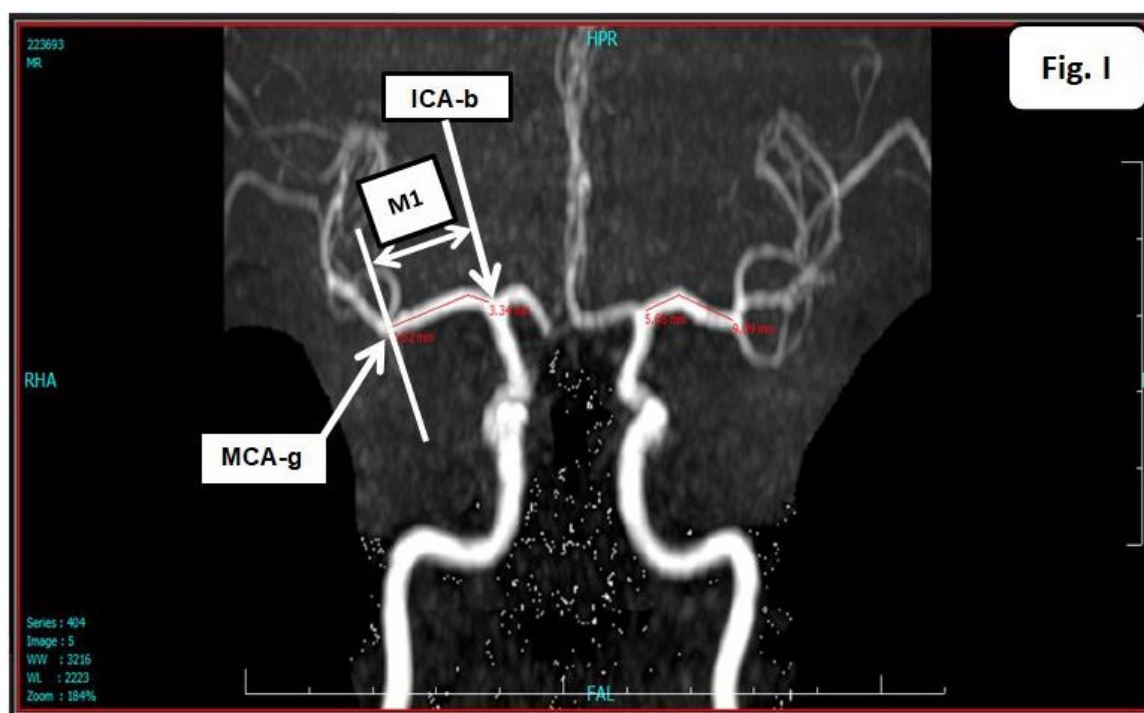


Fig. I: Magnetic resonance angiograph illustrating the proximal segment (M1) of middle cerebral artery which is the part located between the internal carotid artery bifurcation (ICA-b) and the middle cerebral artery genu (MCA-g).

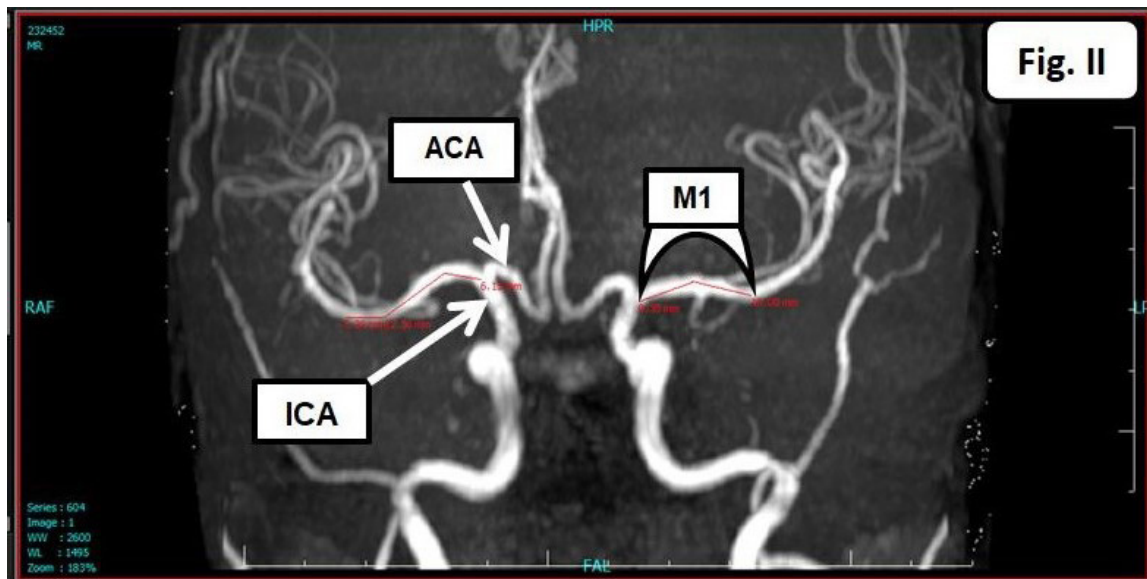


Fig. II: Magnetic resonance angiograph showing the way of measuring the length (red line) of the proximal segment (M1) of middle cerebral artery. Note the internal carotid artery (ICA) and anterior cerebral artery (ACA).

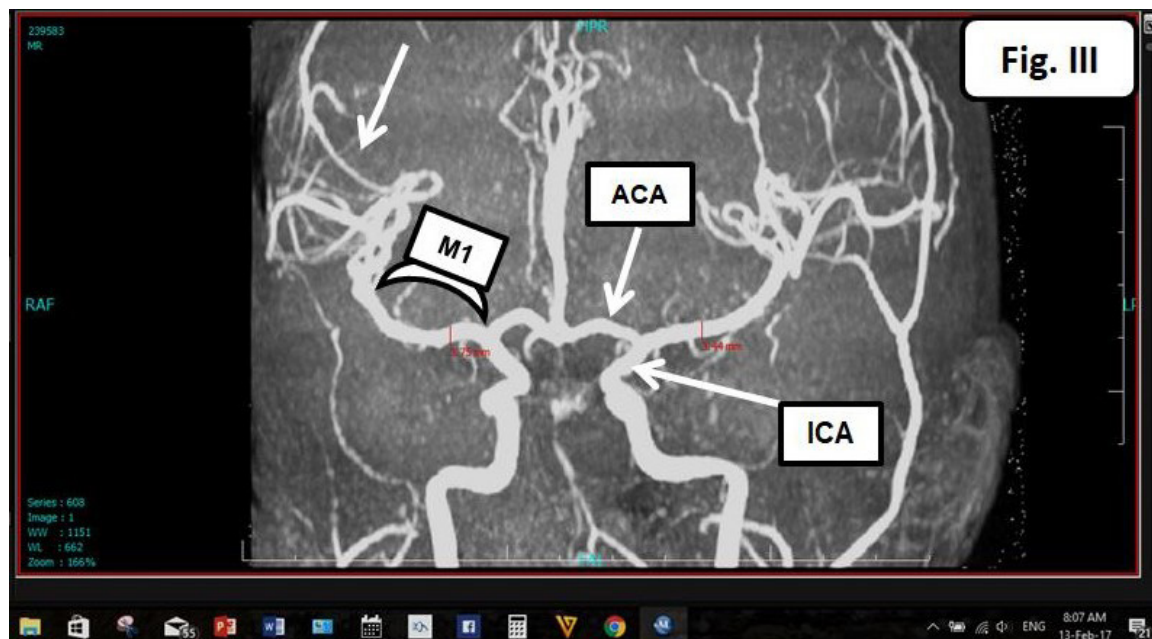


Fig. III: Magnetic resonance angiograph revealing the way of measuring the diameter (red line) of the proximal segment (M1) of middle cerebral artery. Note the internal carotid artery (ICA) and anterior cerebral artery (ACA).

RESULTS

The age of the individuals ranged from 21 to 55 years with mean age (\pm SD) was 43 (\pm 9.03) years.

They were distributed as 22 (27.5%) females and 58 (72.5%) males as shown in (Tables 1 and 2).

Table 1: Distribution of sex (n=80)

	Frequency	Percent (%)
Female	22	27.5%
Male	58	72.5%
Total	80	100%

n: number

Table 2: Minimum, maximum, mean (years) \pm SD of the age of the studied cases (n=80)

	Minimum	Maximum	Mean age (years) \pm SD
Age	21.00	55.00	42.78 \pm 9.04

SD: Standard deviation; **n:** number

1. Side differences of the descriptive measurements of the length and diameter of the proximal segment (M1) of middle cerebral artery (MCA) in all studied cases and their statistical results (Table 3):

The mean (mm) \pm SD of the length of M1 of MCA on the right and left sides was 22.69 mm \pm 5.36 and 22.09mm \pm 5.69, respectively. The range of length was between 12.88-34.90 mm and 11.78-37.13mm on the right and left sides, respectively.

The mean (mm) \pm SD of diameter of M1 of MCA on the right and left sides was 3.60 \pm 0.074 and 3.60 \pm 0.065, respectively. The range of diameter of M1 was between 2.39 - 4.88 mm and 2.48 - 4.95mm on the right and left sides, respectively. There was statistically non-significant ($p > 0.05$) side difference regarding M1 length and diameter.

2. Sex differences of the descriptive measurements of the length and diameter of the

proximal segment (M1) of middle cerebral artery (MCA) on both sides and their statistical results (Tables 4, 5):

In male, the mean (mm) \pm SD of the length of M1 of MCA on the right and left sides was 23.89 \pm 5.20 and 22.26 \pm 5.26, respectively. While in female, the mean (mm) \pm SD of the length of M1 of MCA on the right and left sides was 19.53 \pm 4.50 and 21.65 \pm 6.81, respectively. There was statistically significant increase

($p = 0.001$) regarding the M1 segment length on the right side but there was no sex difference of M1 length on the left side.

In male, the mean (mm) \pm SD of diameter of M1 of MCA on the right and left sides was 3.66 \pm .68 and 3.53 \pm .69, respectively. In female, the mean (mm) \pm SD of diameter of M1 of MCA on the right and left sides was 3.43 \pm .59 and 3.62 \pm .78. There was statistically non-significant ($p > 0.05$) sex difference regarding M1 diameter on both sides.

Table 3: Descriptive statistics of the length and diameter measurements of proximal segment of middle cerebral artery on the right and left sides in all studied cases (n= 80)

Measurements	Minimum	Maximum	Mean (mm) \pm SD	<i>p value</i>
RT M1 length	12.88	34.90	22.69 \pm 5.36	.378 (NS)
LT M1 length	11.78	37.13	22.09 \pm 5.69	
RT M1 diameter	2.39	4.88	3.60 \pm .66	.908 (NS)
LT M1 diameter	2.48	4.95	3.60 \pm .58	

SD: Standard deviation; **RT M1:** proximal segment of middle cerebral artery on right side; **LT M1:** proximal segment of middle cerebral artery on left side; **n:** number; **NS:** non-significant ($p > 0.05$)

Table 4: Descriptive statistics of the length measurements of proximal segment of middle cerebral artery on the right and left sides in both sexes (m= 58, f=22)

Measurements	Mean (mm) \pm SD	<i>p value</i>
RT M1 length in male	23.89 \pm 5.20	0.001**
RT M1 length in female	19.53 \pm 4.50	
LT M1 length in male	22.26 \pm 5.26	.67 (NS)
LT M1 length in female	21.65 \pm 6.81	

SD: Standard deviation; **RT M1:** proximal segment of middle cerebral artery on right side; **LT M1:** proximal segment of middle cerebral artery on left side; **m:** number in male; **f:** number in female; **: highly significant $p \leq 0.001$; **NS:** non-significant ($p > 0.05$)

Table 5: Descriptive statistics of the diameter measurements of proximal segment of middle cerebral artery on the right and left sides in both sexes (m= 58, f=22)

Measurements	Mean (mm) ± SD	p value
RT M1 diameter in male	3.66±.68	0.15 (NS)
RT M1 diameter in female	3.43±.59	
LT M1 diameter in male	3.53±.69	.65 (NS)
LT M1 diameter in female	3.62±.78	

SD: Standard deviation; **RT M1:** proximal segment of middle cerebral artery on right side; **LT M1:** proximal segment of middle cerebral artery on left side; **m:** number in male; **f:** number in female; **NS:** non-significant ($p > 0.05$)

3. Correlations between the mean length and diameter of M1 segment of MCA on both sides; right and left in all studied cases (Table 6):

There was statistically significant positive correlation ($r= .410, p= .000$) between mean length of M1 segment on both right and left sides.

There was statistically significant positive correlation ($r= .348, p= .002$) between mean length of M1 segment on the right side and mean diameter of M1 segment on the right side.

There was statistically significant positive correlation ($r= .266, p= .017$) between mean

length of M1 segment on the right side and mean diameter of M1 segment on the left side.

There was statistically significant positive correlation ($r= .377, p= .002$) between mean length of M1 segment on the left side and mean diameter of M1 segment on the right side.

There was statistically significant positive correlation ($r= .256, p= .022$) between mean length of M1 segment on the left side and mean diameter of M1 segment on the left side.

There was statistically significant positive correlation ($r= .605, p= .000$) between mean diameters of M1 segment on the right and left sides.

Table 6: Correlations between the mean length and diameter of M1 segment of middle cerebral artery (MCA) on both sides in all studied cases (n=80)

		RT M1 length	LT M1 length	RT M1 diameter	LT M1 diameter
RT M1 length	Pearson Correlation	1	.410**	.348**	.266*
	Sig. (2-tailed)		.000	.002	.017
LT M1 length	Pearson Correlation	.410**	1	.337**	.256*
	Sig. (2-tailed)	.000		.002	.022
RT M1 diameter	Pearson Correlation	.348**	.337**	1	.605**
	Sig. (2-tailed)	.002	.002		.000
LT M1 diameter	Pearson Correlation	.266*	.256*	.605**	1
	Sig. (2-tailed)	.017	.022	.000	

RT M1: proximal segment of MCA on right side; **LT M1:** proximal segment of MCA on left side; **n:** number
 **. Correlation is highly significant at the 0.01 level (2-tailed). *. Correlation is significant at the 0.05 level (2-tailed).

4. Number of divisions (branches) of proximal segment of MCA in all studied cases on both sides (Table 7 and Pie chart 1):

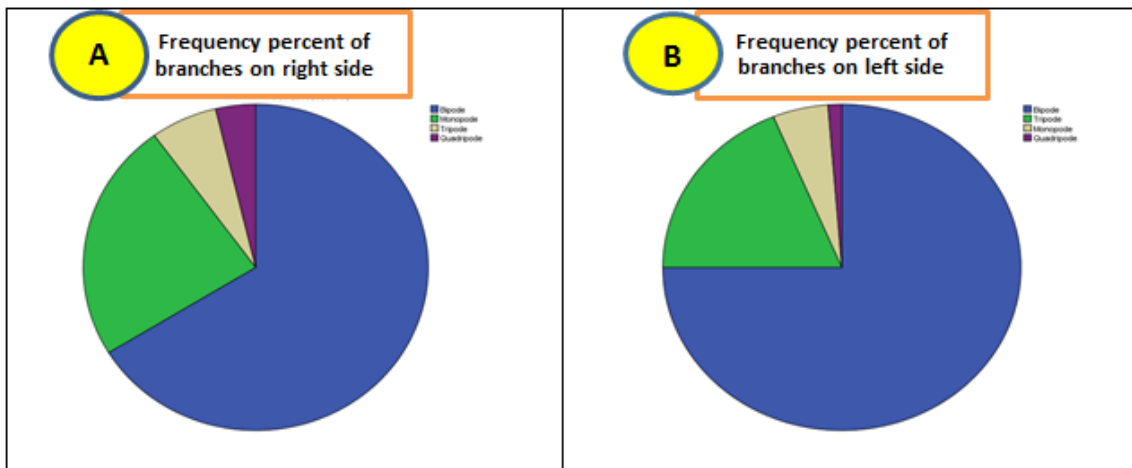
On the right side, the branches of M1 segment of MCA was bipode (Figs. 1, 6, 7) in 53 (66.3%),

monopode (Figs. 2, 3) in 19 (23.8%), tripode (Fig. 4) in 5 (6.3%) and quadripode (Fig. 5) in 3 (3.8%) of cases. While on the left side, the divisions of M1 segment of MCA was bipode (Figs. 1,3,7) in 60 (75%), tripode (Figs. 4, 5) in 15 (18.8%), monopode (Fig. 2) in 4 (5%) and quadripode (Fig. 6) in 1 (1.3%) of studied cases.

Table 7: Frequency and percent of divisions of M1 segment of MCA in all studied cases on both sides (n=80)

Number of division of M1 segment	Right side		Left side	
	Frequency (%)	Cumulative	Frequency (%)	Cumulative Percent
Bipode	53 (66.3%)	66.3	60 (75%)	75.0
Monopode	19 (23.8%)	90.0	15 (18.8%)	93.8
Tripode	5 (6.3%)	96.3	4 (5%)	98.8
Quadripode	3 (3.8%)	100.0	1 (1.3%)	100.0
Total	80 (100%)		80 (100%)	

M1: proximal segment of middle cerebral artery; **MCA:** middle cerebral artery; **n:** number



Pie chart (1): Showing the frequency percent of divisions of the proximal segment of middle cerebral artery in all studied cases on the right (A) and left (B) sides.

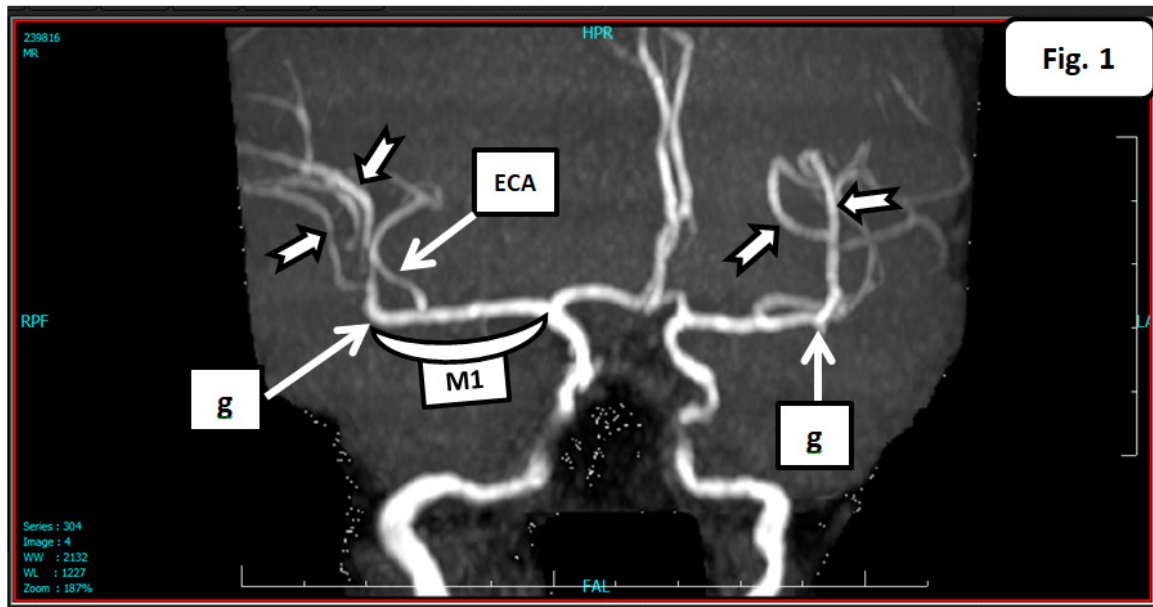


Fig. 1: Magnetic resonance angiograph displaying bilateral bipode (arrows) division of the proximal segment (M1) of middle cerebral artery, distal to genu (g) on both sides. Note early cortical artery (ECA) on the right side.

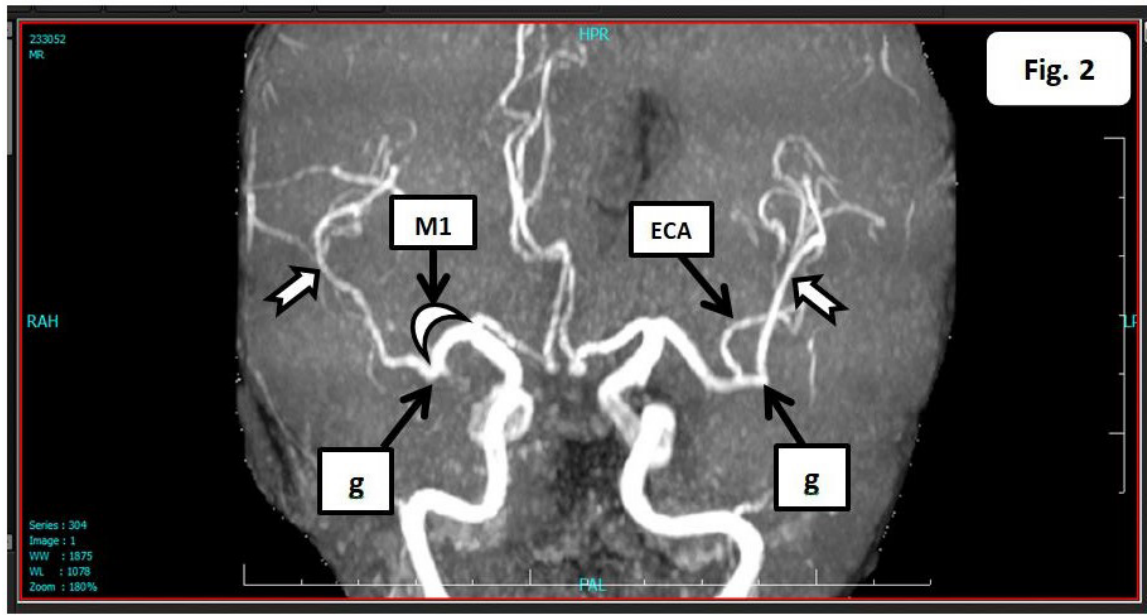


Fig. 2: Magnetic resonance angiograph revealing bilateral monopode (arrows) division of the proximal segment (M1) of middle cerebral artery, distal to genu (g) on both sides. Note early cortical artery (ECA) on the left side.

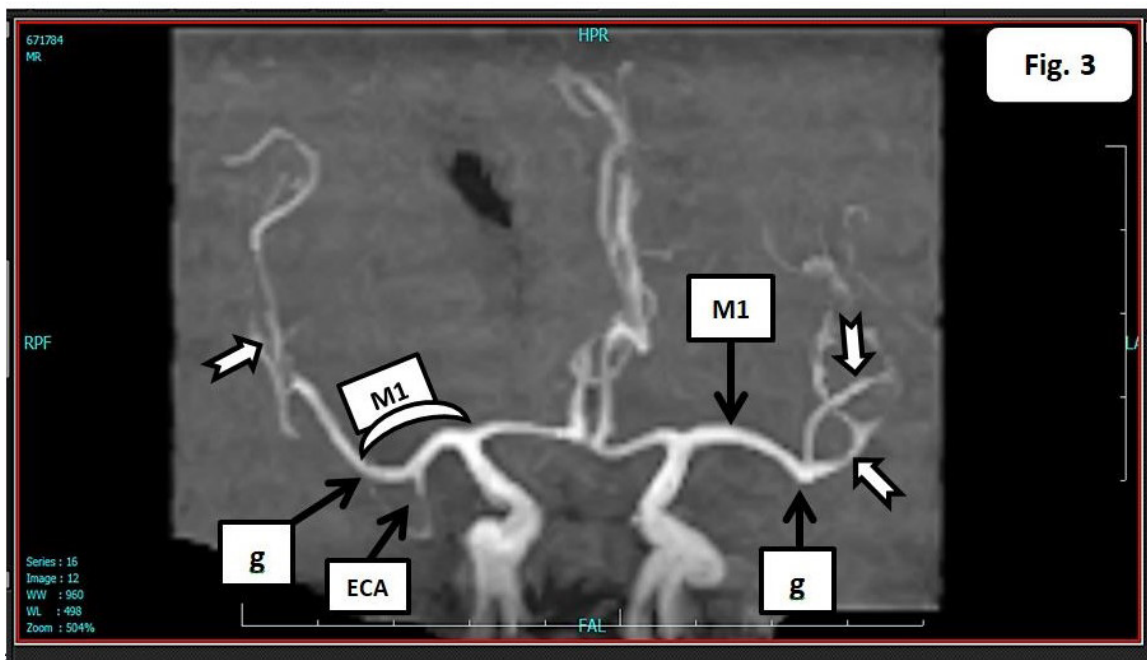


Fig. 3: Magnetic resonance angiograph demonstrating right-sided monopode (arrow) and left-sided bipode (arrows), at the genu (g) of proximal segment (M1) of middle cerebral artery. Note early cortical artery (ECA) on the right side.

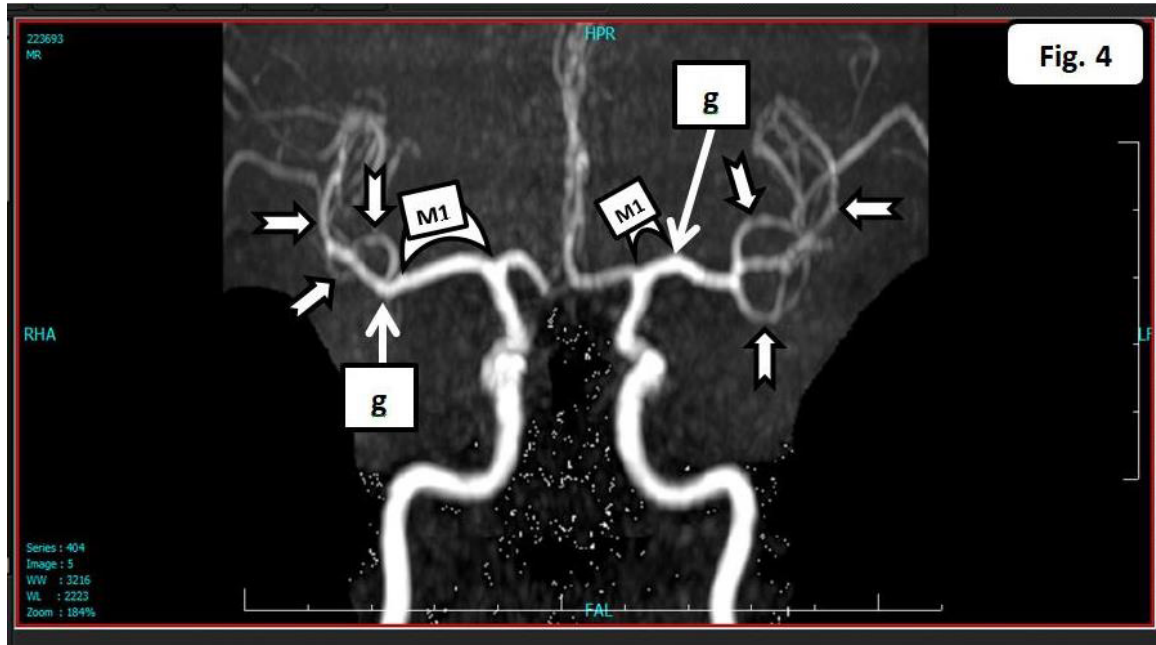


Fig. 4: Magnetic resonance angiography image showing bilateral tripod (arrows) division of the proximal segment (M1) of middle cerebral artery, distal to genu (g).

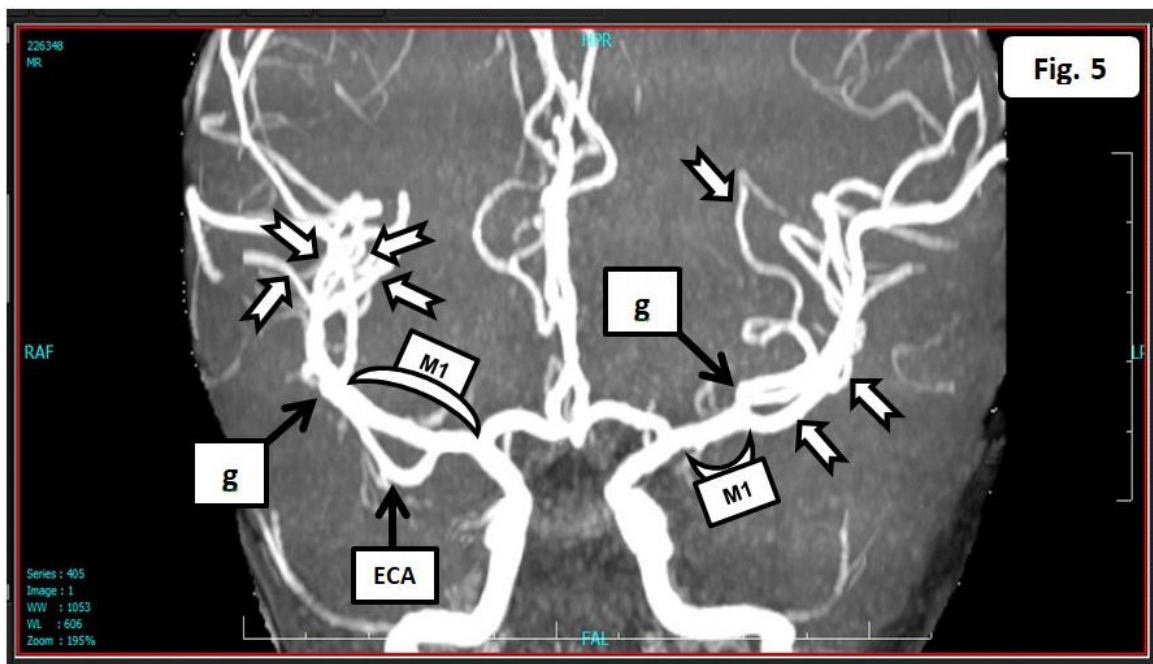


Fig. 5: Magnetic resonance angiography image revealing right-sided quadripode (arrows) division of the proximal segment (M1) of middle cerebral artery, distal to genu (g) and left-sided tripod (arrows) division at the genu (g). Note early cortical artery (ECA) on the right side.

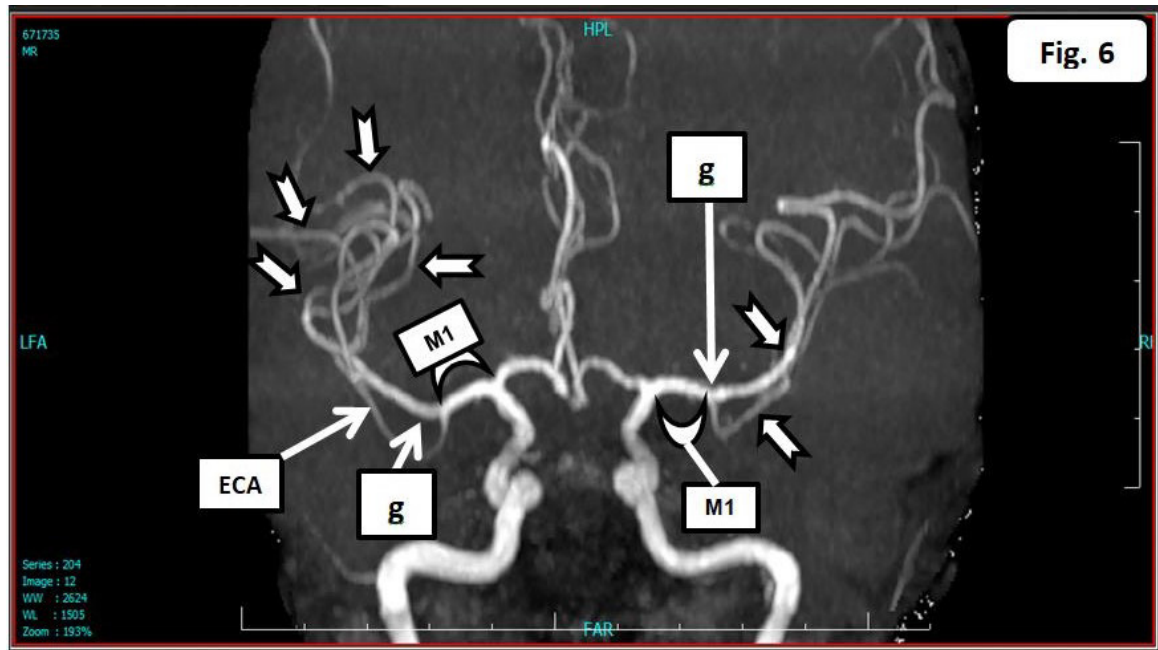


Fig. 6: Magnetic resonance angiography image showing left-sided quadripartite (arrows) division of the proximal segment (M1) of middle cerebral artery, distal to genu (g). Right-sided bipartite (arrows) division of the proximal segment (M1) of middle cerebral artery is also seen, at genu (g). Note early cortical artery (ECA) on the left side.

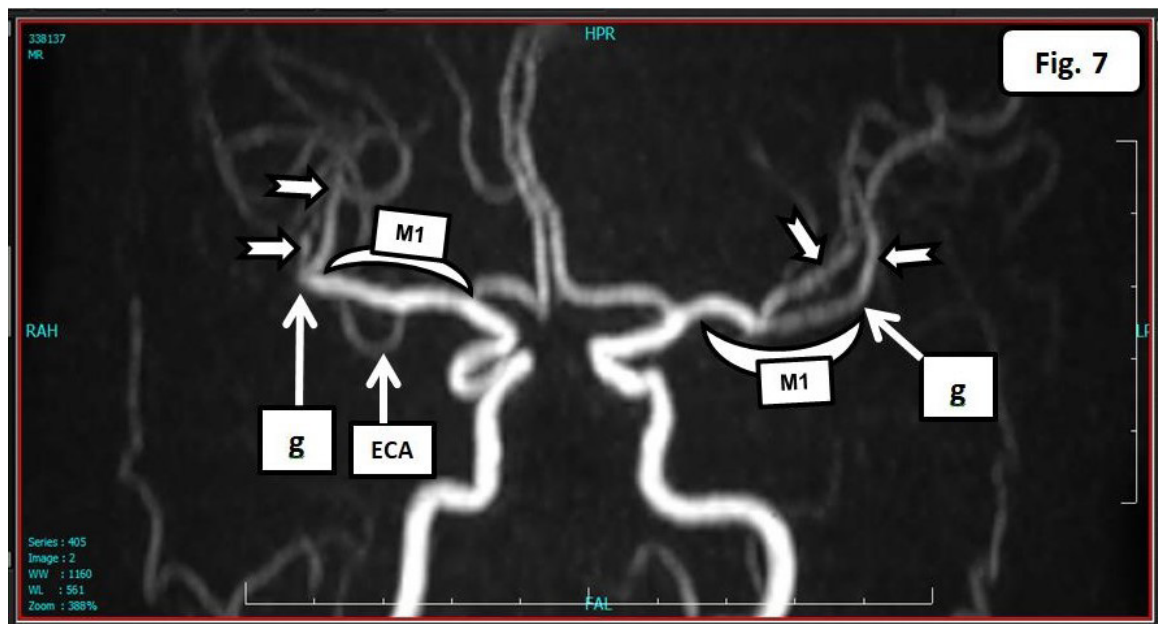


Fig. 7: Magnetic resonance angiography image demonstrating right-sided bipartite (arrows) division of the proximal segment (M1) of middle cerebral artery, at genu (g) and left-sided bipartite division proximal to genu (g). Note early cortical artery (ECA) on the right side.

5. Site of division of M1 segment in relation to the genu (Table 8 and bar chart 1):

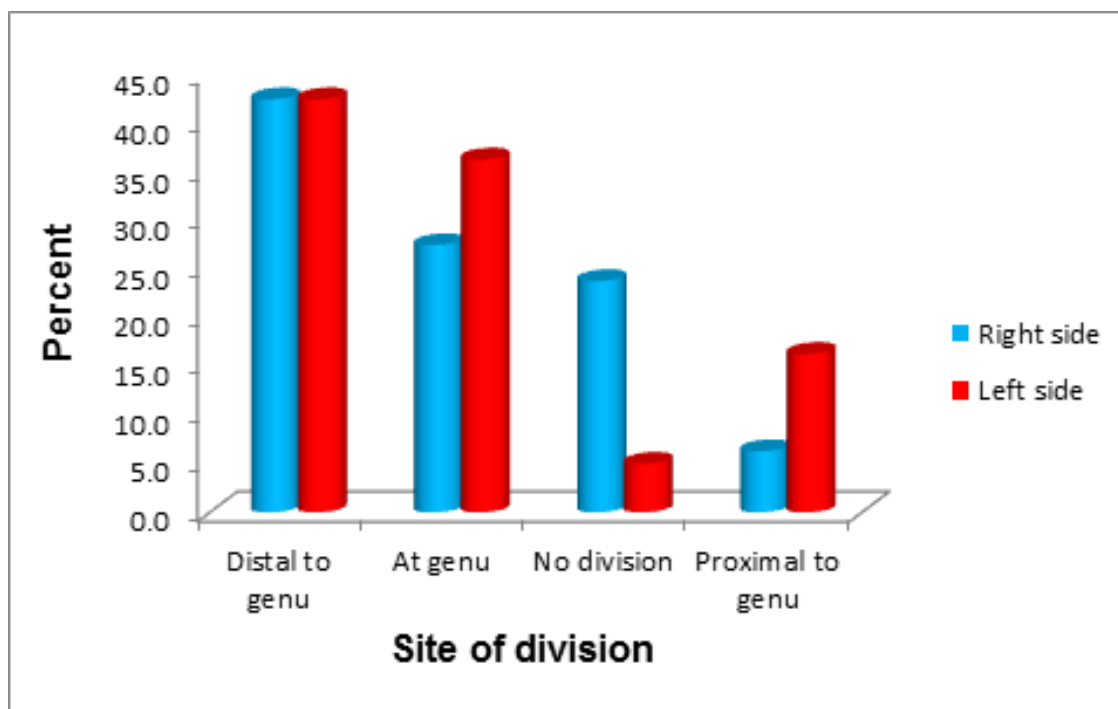
The division of M1 segment was observed distal to the genu in 34 (42.5%) of cases on both the right (Figs. 1, 2, 5) and left (Figs. 1, 2, 4, 6) sides. While the division occurred at the level of genu on the right side (Fig. 6, 7) in 22 (27.5%) and

on the left side (Figs. 3, 5) in 29 (36.3%) Division proximal to the genu was recorded in 5 (6.3%) and 13 (16.3%) of cases on the right and left (Fig. 7) sides, respectively. There was no division (monopode) of M1 segment in 19 (23.8%) and 4 (5%) of cases on the right (Figs. 2, 3) and left sides (Fig. 3), respectively.

Table 8: Frequency and percent of site of division in relation to genu of M1 segment of MCA on both sides

Level of division	Right side		Left side	
	Frequency (%)	Cumulative Percent	Frequency (%)	Cumulative Percent
Distal to genu	34 (42.5%)	70.0%	34 (42.5%)	78.8%
At genu	22 (27.5%)	27.5%	29 (36.3%)	36.3%
No division	19 (23.8%)	93.8%	4 (5%)	83.8%
Proximal to genu	5 (6.3%)	100.0%	13 (16.3%)	100%
Total	80 (100%)		80 (100%)	

M1: proximal segment of middle cerebral artery; **MCA:** Middle cerebral artery



Bar chart (1): Showing the frequency percent of division of proximal segment of middle cerebral artery in relation to genu, on both sides.

6. Course of M1 segment (Tables 9, 10 and pie chart 2):

At a transverse plane, M1 segment was seen most frequently concave posteriorly in 42(52.5%) and 44 (55%) of cases on the right and left sides, respectively. The course of M1 segment was observed straight in 27 (33.8%) and 28(35%) of cases on the right and left sides respectively.

While the concave anteriorly course of M1 was the least noticed in 11(13.8%) and 8(10%) on the right and left sides, respectively.

The course of M1 segment of MCA was bilaterally concave anteriorly in 4 of the studied cases and bilaterally concave posteriorly in 35 of the studied cases. In addition, bilateral straight course was found in 15 of the studied cases.

Table 9: Frequency and percent of the course of M1 segment of middle cerebral artery on the right and left side of all studied cases (n=80)

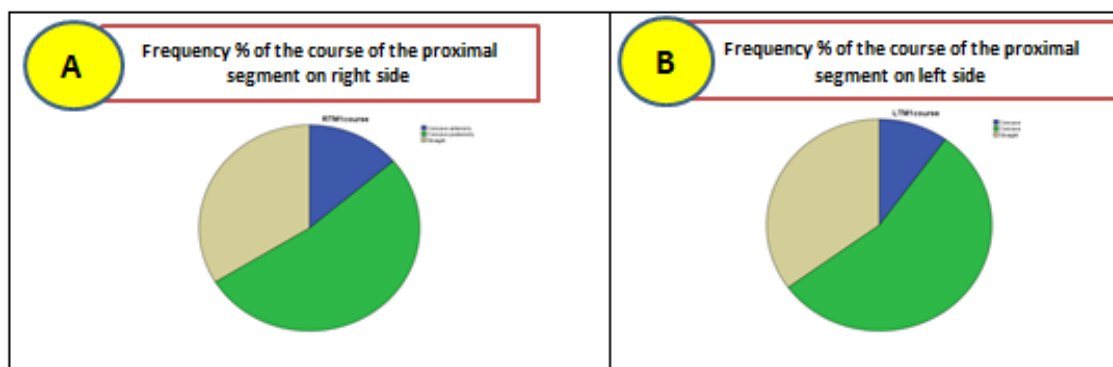
Course of M1 segment	Right side		Left side	
	Frequency (%)	Cumulative Percent	Frequency (%)	Cumulative Percent
Concave posteriorly	42 (52.5)	66.3	44 (55)	65
Straight	27 (33.8)	100.0	28 (35)	100
Concave anteriorly	11 (13.8)	13.8	8 (10)	10
Total	80 (100)		80 (100)	

M1: proximal segment of middle cerebral artery; **n:** number

Table 10: Cross tabulation of the course of M1 segment of MCA on both sides (n=80)

		The course of M1 segment on left side			Total
		Concave anteriorly	Concave posteriorly	Straight	
The course of M1 segment on right side	Concave anteriorly	4	3	4	11
	Concave posteriorly	1	35	6	42
	Straight	3	6	18	27
	Total	8	44	28	80

M1: proximal segment of middle cerebral artery; **MCA:** middle cerebral artery; **n:** number



Pie chart (2): Showing the frequency percent of the course of the proximal segment of middle cerebral artery in all studied cases on the right (A) and left (B) sides.

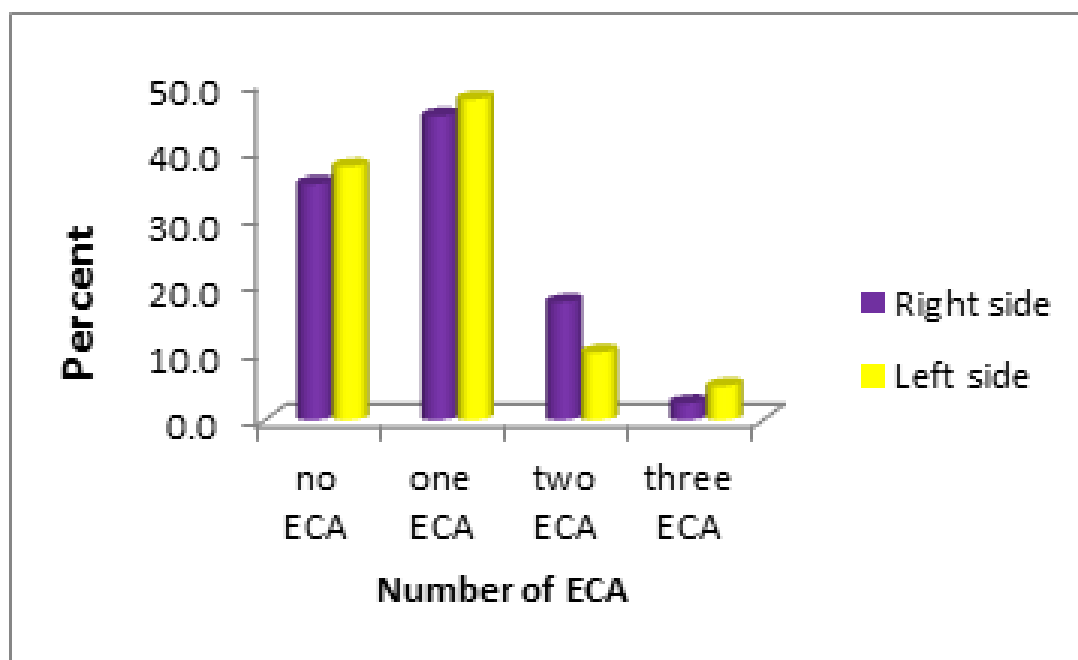
7. Number of early cortical artery (ECA) (Table 11 and bar chart 3):

Early cortical artery was absent in 35% and found in 65% of all studied cases (Figs. 1-3, 5-7); one ECA was observed in 36 (45%) and 38 (47.5 %) of cases on the right and left sides,

respectively. Two ECA was encountered in 14(17.5%) and 8(10%) of cases on the right and left sides, respectively. Three ECA was found in 2 (2.5%) and 4 (5%) of cases on the right and left sides, respectively.

Table 11: Frequency of the number of early cortical artery on both sides

Number of ECA	Right side		Left side	
	Frequency (%)	Cumulative Percent	Frequency (%)	Cumulative Percent
No ECA	28 (35)	35.0	30 (37.5)	37.5
One ECA	36 (45)	80.0	38 (47.5)	85.0
Two ECA	14 (17.5)	97.5	8 (10)	95.0
Three ECA	2 (2.5)	100.0	4 (5)	100.0
Total	80 (100)		80 (100)	

**Bar chart (3):** Showing frequency percent of the number of early cortical artery (ECA) on the right and left sides.

DISCUSSION

There are several morphological variations in the anatomy of middle cerebral artery (MCA), so researches were carried out to evaluate such differences. In the present work, we used 3D magnetic resonance angiography images to study the major anatomical variations of the proximal segment of middle cerebral artery.

The proximal part of the middle cerebral artery is commonly called the M1 segment that is defined by Gibo *et al.*^[13]. This segment has also other names like the horizontal as mentioned earlier by Herman *et al.*^[14] or sphenoidal segment as stated by Gibo *et al.*^[13]. The later author has described the M1 segment in relation to the surrounding cerebral structures, from its beginning to its termination. Accordingly, the course of M1 segment has been illustrated on

angiographic base as it begins laterally near to the optic chiasm, at the level of the medial end of the lateral fissure and passes towards the insula laterally with its location behind the anterior perforated substance^[15].

In the present study, the mean length of M1 segment of MCA was 22.69 mm \pm 5.36 and 22.09 mm \pm 5.69, on the right and left sides, respectively. These measurements nearly similar to those found by Vuillier *et al.*^[11] who reported that the mean length of M1 of MCA was 23.0 mm on both sides. In the present work, the mean length of M1 of MCA on the right and left sides was 23.89 and 22.26, respectively. While in female, the mean length of M1 of MCA on the right and left sides was 19.53 and 21.65, respectively. There was statistically significant increase regarding the M1 segment length on the right side. Earlier, Grellier *et al.*^[16] ranged the length of the proximal segment

of MCA into short length (3-12 mm), medium (13-22 mm) or long (23-40 mm). Moreover, Zurada *et al.*^[17] added that the shorter length of M1 of MCA would have an important role in the production of the vascular aneurysms

In the present work, the mean (mm) \pm SD of diameter of M1 segment of MCA on the right and left sides was 3.60 ± 0.66 and 3.60 ± 0.58 , respectively. This meets the finding that observed by Pai *et al.*^[2] and Vuillier *et al.*^[11], but differs from the result of Tarasów *et al.*^[18] who found that MCA diameter was 2.23 ± 0.41 mm. Tanriover *et al.*^[1] reported that the diameter of M1 segment differs according to the location of measurement; at its beginning, the diameter was 5mm, with an average of 4mm. Additionally, Vuillier *et al.*^[11] found that the diameter of M1 segment decreased at its middle (3mm) and this confirmed the mild decrease in M1 diameter towards its termination. These findings of the intraluminal diameter of M1 segment have been technically applied for grading the severity of its narrowing using conventional arteriography, angio CT scan, magnetic resonance angiography (MRA), or when doing percutaneous angioplasty or putting in place an intraluminal stent^[19]. Moreover, Zurada *et al.*^[17] added that variations in the width may refer to specific diseases

In the current work, there was statistically non-significant difference regarding the length and diameter of M1 of MCA on both right and left sides of all studied cases. Similar result was observed by Tarasów *et al.*^[18] who stated that no variations were noticed between the lengths of the different segments of MCA on both sides of cerebrum. Also, the authors reported longer segments of MCA with increase age, but statistically non-significant.

In the present research, there was a positive correlation between the mean length and diameter of MCA on both sides. However, no corresponding finding was described by previous studies.

In the present study, the division of M1 segment was frequently bipode on the right and left sides by 66.3% and 75%, respectively. However, the least division was quadripode on the right and left sides by 3.8% and 1.3% of cases, respectively. Earlier in Nigerian cases, Idowu *et al.*^[20] demonstrated M1 segment termination in a bipode manner (81%), tripode (13 %) and monopode (6 %). In Croatian

cases, Kulenovic *et al.*^[21] demonstrated bipode and tripode termination of MCA in 70% of and 30% of cases, respectively. In American individuals, Tanriover *et al.*^[1] described termination of M1 segment of MCA as bipode in 88% and tripode in 12% of studied cases. *et al.*^[2] found a bipode bifurcation of M1 segment in 80% and tripode termination of M1 in 20% of cases. Later on, Vuillier *et al.*^[11] reported bipode division of M1 segment in 73%, tripode in 9% and monopode in 18% of French cases. In Kenyan persons, modes of M1 termination were bifurcation (82.3%), trifurcation (10.8%), primary trunks (6.2%), and quadrifurcation (0.7%)^[22]. More recent, the study on middle cerebral artery revealed bifurcation pattern of division in 73% and trifurcation in 27% of the studied Indian cases^[23]. Variable percentage of termination of M1 segment could be attributed to variations in the methods of examination and different geographical races.

Quadripode termination of M1 segments were only described in the present study and in Kenyan cases as reported by Ogeng'o *et al.*^[22] and this could be attributed to the similar African races. However, Hosoda *et al.*^[24] and Iwamoto *et al.*^[25] pointed out that bifurcated or trifurcated M1 segment has a higher incidence of aneurysm formation which was claimed by Ingebrigtsen *et al.*^[26] that blood turbulence stress is present at the site of division of the artery. Futrell *et al.*^[27] reported tripode manner termination of M1 segment and found this is a common site of blood emboli and explained this by the sudden narrowing of the originating arteries. Description of different pattern of termination of M1 segment of MCA has a great value in surgical repair of aneurysm and diagnosis of cerebral stroke.

The division of M1 segment was observed most frequently distal to the genu in 42.5% of the cases of the present study on both the right and left sides. While the division occurred at the level of genu in 27.5% and 36.3% on the right and left sides, respectively. Vuillier *et al.*^[11] reported vast majority of division of M1 segment at genu by 75% of studied cases. Division proximal to the genu was recorded in 6.3% and 16.3% of cases on the right and left sides, respectively. Teal *et al.*^[28] and Anderhuber *et al.*^[29] declared that early division (proximal to genu) of M1 segment of MCA occurred in 5.2% of cases and indicated that in those cases a higher possibility of aneurysm formation is expected. More recent, Brzegowy

et al.^[30] demonstrated division of MCA proximal to genu in 78.4%, at genu in 19.2% and distal to genu in 2.4% of the studied images.

In the present work, at a transverse plane, M1 segment was seen most frequently concave posteriorly in 52.5% and 55% of Egyptian cases on the right and left sides, respectively. The course of M1 segment was observed straight in 33.8% and 35% of cases on the right and left sides respectively. While the concave anterior course of M1 was the least noticed in 13.8% and 10% on the right and left sides, respectively. However, Vuillier *et al.*^[11] demonstrated straight course of M1 segment in the majority of studied cases and the concave anterior course of M1 segment in the least number of studied cases.

In the present study, early cortical artery was found in 65%; one ECA was observed most frequently in 45 % and 47.5 % of Egyptian cases on the right and left sides, respectively. Three ECA was found least frequent in 2.5 % and 5 % of cases on the right and left sides, respectively. Early cortical branches were found in 46% of a French population by Vuillier *et al.*^[11] and 47% of an African population by Ogeng'o *et al.*^[22]. Presence of more number of early cortical was associated with increased incidence of aneurysm formation^[31].

Using 3D magnetic resonance angiography in the present work gives more knowledge about the anatomical morphological and morphometric variations of the proximal segment of middle cerebral artery. These results are useful for the clinicians and neurosurgeons and gave them some guidelines important in their approach to middle cerebral artery specially its proximal segment.

CONFLICT OF INTERESTS

There are no conflicts of interest.

REFERENCES

1. Tanriover, N., Kawashima, M., Rhoton, A.L., Ulm, A.J., Mericle, R.A. (2003). Microsurgical anatomy of the early branches of the middle cerebral artery: morphometric analysis and classification with angiographic correlation. *J Neurosurg.*; 98:1277–1290.
2. Pai, S.B., Varma, R.G., Kulkarni, R.N. (2005). Microsurgical anatomy of the middle cerebral artery. *Neurol. India.*; 53: 186 – 190.
3. Kathuria, S., Gregg, L., Chen, J., *et al.* (2011). Normal cerebral arterial development and variations. *Semin Ultrasound CT MR.*; 32(3): 242–251.
4. Umansky, F., Juarez, S.M., Dujovny, M. *et al.* (1984). Microsurgical anatomy of the proximal segments of the middle cerebral artery. *J Neurosurg.*; 61:458–467.
5. Yasargil, M.G. (1984). Middle cerebral artery, *Microneurosurgery*, vol 1. Georg Thieme Verlag, Stuttgart, pp. 72–91.
6. Martinez, F., Spagnuolo, E., Calvo-Rubal, A., *et al.* (2004). Variants of the anterior circle of Willis. Anatomic and angiographic correlation and its implications in the surgery of intracranial aneurysms. (Acigos anterior cerebral artery, median artery of the corpus callosum and accessory middle cerebral artery). *Neurocirugia (Astur)*, 2004; 15: 578–88.
7. Słowik A, Wnuk M, Brzegowy P, *et al.* (2017). Polish Thrombectomy Initiative. Mechanical thrombectomy in acute stroke – Five years of experience in Poland. *Neurol Neurochir Pol.*; 51(5): 339–346.
8. Huttunen, T., von und zu Fraunberg, M., Frösen, J., *et al.* (2010). Saccular intracranial aneurysm disease: distribution of site, size, and age suggests different etiologies for aneurysm formation and rupture in 316 familial and 1454 sporadic eastern Finnish patients. *Neurosurgery*; 66(4): 631–638.
9. Kahilogullari, G., Ugur, H.C., Comert, A., *et al.* (2012). The branching pattern of the middle cerebral artery: is the intermediate trunk real or not? An anatomical study correlating with simple angiography. *J Neurosurg.*; 116(5): 1024–1034.
10. Choi, C.G., Lee, D.H., Lee, J.H., Pyun, H.W., Kang, D.W., Kwon, S.U. *et al.* (2007). Detection of intracranial atherosclerotic steno-occlusive disease with 3D time of

- Xight magnetic resonance angiography with sensitivity encoding at 3T. *AJNR Am J Neuroradiol.*; 28:439–446.
11. Vuillier, F., Medeiros, E., Moulin, T., Cattin, F., Bonneville, J.F., Tatu, L. (2008). Main anatomical features of the M1 segment of the middle cerebral artery: a 3D time-of-flight magnetic resonance angiography at 3 T study. *Surg Radiol Anat.*; 30:509–514.
 12. Petrie, A. and Sabin, C. (2005). Medical statistics at a glance, 2nd edi., In: Sugden, M., Moore, K. (Eds). Blackwell Publishing LTD. USA. pp. 55.
 13. Gibo, H., Carver, C.C., Rhoton, A.L., Lenkey, C., Mitchell, R.J. (1981). Microsurgical anatomy of the middle cerebral artery. *J Neurosurg.*; 54:151–169.
 14. Herman, L.H., Ostrowski, A.Z., Gurdjian, E.S. (1963). Perforating branches of the middle cerebral artery; an anatomical study. *Arch Neurol (chic.)*; 8:32–34.
 15. Krayenbuhl, H.A., Yasargil, M.G. (1968). *Cerebral angiography*. Butterworth, London, pp. 58–60.
 16. Grellier, P., Roche, J.L., Duplay, J. (1978). Radio-anatomical study of the main trunk of the middle cerebral artery. *Neurochirurgie*; 24(4):227-233.
 17. Zurada, A., Gielecki, J., Tubbs, R.S., Loukas, M., Cohen-Gadol, A.A., Chlebiej, M., et al. (2010). Three-dimensional morphometry of the A2 segment of the anterior cerebral artery with neurosurgical relevance. *Clin Anat.*; 23(7):759-769.
 18. Tarasów, E., Ali, A.A.S., Lewszuk, A., Walecki, J. (2007). Measurements of the middle cerebral artery in digital subtraction angiography and MR angiography. *Med Sci Monit.*; 13(Suppl 1): 65-72.
 19. Lee, T.H., Kim, D.H., Lee, B.H., Kim, H.J., Choi, C.H. *et al.* (2005). Preliminary results of endovascular stent-assisted angioplasty for symptomatic middle cerebral artery stenosis. *Am J Neuroradiol.*; 26:166–174.
 20. Idowu, O.E., Shokunbi, M.T., Malomo, A.O., Ogunbiyi, J.O. (2002). Size, course, distribution and anomalies of the middle cerebral artery in adult Nigerians. *East Afr Med J.*; 79:217–220.
 21. Kulenovic, A., Dilberovic, F., Ovcina, F. (2003). Variation in the flow and branching of the anterior and middle cerebral arteries. *Med Arh* 57:3–5.
 22. Ogeng’o, J.A., Olabu, B.O., Kilonzi, J.P., Sinkeet, S.R., Muthoka, J.M. (2009). Intracranial aneurysms in an African country. *Neurol India.*; 57:613–616.
 23. Jeyakumar, R. and Veerapandian, R. (2018). Study of Anatomical Variations in Middle Cerebral Artery. *International Journal of Scientific Study*; 5(12): 5-10.
 24. Hosoda, K., Fujita, S., Kawaguchi, T., Shose, Y., Hamano, S. (1995). Saccular aneurysms of the proximal (M1) segment of the middle cerebral artery. *Neurosurgery*; 36:441–446.
 25. Iwamoto, H., Kiyohara, Y., Fujishima, M., Kato, I., Nakayama, K., Sueishi, K., *et al.* (1999). Prevalence of intracranial saccular aneurysms in a Japanese community based on a consecutive autopsy series during a 30-year observation period. The Hisayama study. *Stroke*; 30:1390–1395.
 26. Ingebrigtsen, T., Morgan, M.K., Faulder, K., Ingebrigtsen, L., Sparr, T., Schirmer, H. (2004). Bifurcation geometry and the presence of cerebral artery aneurysms. *J Neurosurg.*; 101:108–113.
 27. Futrell, N. (1998). Pathophysiology of acute ischemic stroke: New concepts in cerebral embolism. *Cerebrovasc Dis.*; 8 (Suppl 1):2–5.
 28. Teal, J.S., Rumbaugh, C.L., Bergeron, R.T., Segall, H.D. (1973). Anomalies of the middle cerebral artery: Accessory artery, duplication, and early bifurcation. *Am J Roentgenol Radium Ther Nucl Med.*; 118:567–575.
 29. Anderhuber, F., Weiglein, A., Pucher, R.K. (1990). Trifurcations of the middle cerebral arteries. *Acta Anat.*; 137:342–349.

30. Brzegowy, P., Polak, J., Wnuk, J., Łasocha, B., Walocha, J., Popiela, T.J. (2018). *Folia Morphol (Warsz.)*; 77(3):434-440.
31. Park, D.H., Kang, S.H., Lee, J.B., Lim, D.J., Kwon, T.H., Chung, Y.G., *et al.* (2008). Angiographic features, surgical management and outcomes of proximal middle cerebral artery aneurysms. *Clin Neurol Neurosurg*; 110:544–551.

الاختلافات التشريحية للجزء القريب من الشريان الدماغى الأوسط وأهميتها الأكلينيكية: دراسة ثلاثية الأبعاد لصور الرنين المغناطيسى للأوعية فى المصرىين

ملخص البحث

الخلفية: يحتاج التدخل الجراحي العصبى والتعامل مع الأوعية الدموية للشريان الدماغى الأوسط الى معرفة المزيد من المعلومات عن التركيب التشريحي لأجزاءه المختلفة خاصة الجزء القريب.

الهدف من البحث: تقييم التغيرات الشكلية والشكلية القياسية المختلفة للجزء القريب للشريان الدماغى الأوسط فى المصرىين. بالاضافة الى تقييم الأهمية الأكلينيكية لمثل هذه التغيرات.

المرضى وطرق البحث: تم إجراء هذا البحث بأثر رجعى على صور ثلاثية الأبعاد للرنين المغناطيسى للأوعية الدموية لعدد ٨٠ من الأشخاص الأصحاء دون أى أمراض بالأوعية المخية. تم تقييم الاختلافات الشكلية وكذلك قياسات الأطوال والأقطار للجزء القريب للشريان المخى الوسط. كما تم تقييم اختلافات القياسات على الجانبين الأيمن والأيسر وكذلك بين الجنسين.

النتائج: لقد وجد فرق مهم احصائيا بين الجنسين فيما يتعلق بطول الجزء القريب من الشريان المخى الأوسط على الجانب الأيمن. بالاضافة الى وجود ارتباط ايجابى على الجانبين الأيمن والأيسر بين القياسات المختلفة للجزء القريب. وكانت فروع الجزء القريب للشريان الدماغى الأوسط معظمهم ثنائى التفرع والأقل رباعى التفرع على كلا الجانبين. وقد لوحظ تقسيم الجزء القريب للشريان الدماغى الأوسط بنسبة كبيرة بعيدا عن اتجاهه لأعلى وللخلف ٥٢,٥% و ٥٢% على الجانبين الأيمن والأيسر بالتتابع. والأقل نسبه تقسيم الجزء القريب قبل اتجاهه الى الخلف ولأعلى بنسبة ١٣,٨% و ١٠% على الجانبين الأيمن والأيسر بالتتابع.

لقد وجد الشريان الدماغى المبكر فى ٦٥% من الحالات.

الاستنتاج: نتائج الاختلافات التشريحية للجزء القريب للشريان الدماغى الأوسط كما تم تقييمها بواسطة التصوير الثلاثى الأبعاد بالرنين المغناطيسى للأوعية مفيدة جدا لتدخلات جراحة المخ والاعصاب.