

<b>Original Article</b>	<b>Curvatures and Medullary Canal of the Clavicle Among an Egyptian Population: A three Dimensional Computed Tomography Study</b> <i>Nabila Adieb Abd El Messih, Mohamed Hafez Shaaban, Magdy Fouad Youakim, Mariam Atef Fahim</i> <i>Anatomy and Embryology Department, Faculty of Medicine, Cairo University, Egypt</i>
-------------------------	---

#### ABSTRACT

**Background:** Clavicle is the most frequently fractured bone in human skeleton. Fractures treated non-operatively showed higher rate of non-union or malunion. Operative treatment have superior results over the non-operative treatment, and include two approaches; external fixation or internal fixation. External fixation may be cosmetically displeasing and uncomfortable. Internal fixation is accompanied by a higher rate of cure with lesser complications, however the shape and size of the medullary canal of the clavicle can be a prohibiting factor making the placement of intramedullary devices difficult.

**Aim of work:** The present work was designed to study the length, the curvatures as well as the dimensions of the medullary canal of the clavicle among Egyptians using three dimensional computed tomography.

**Material and Methods:** This study was carried on one hundred clavicles. CT scan of the chest with coronal and sagittal reformatting and 3D reconstruction of the clavicle was done.

**Results:** The length of male clavicles was longer than female clavicles. Left clavicles were shorter than right clavicle in both sexes. The medial as well as the lateral angle of the left clavicle was greater than that of the right clavicle in both sexes. The height and width of the medullary canal of the clavicle were generally greater in males than in females.

**Conclusion:** Computed tomography imaging has been shown to be an accurate method for describing the anatomy of the clavicle. Data could be used to determine whether the anatomy of the clavicle and its medullary canal were suitable for intramedullary fixation.

**Key Words:** Clavicle, Anatomy, CT, Intramedullary Fixation.

**Corresponding Author:** Magdy Fouad Youakim, Anatomy and Embryology Department, Faculty of Medicine, Cairo University, **Email:** drmagdy@hotmail.com, **Mobile:** 01001423212

#### INTRODUCTION

The clavicle is the first bone in the body to be ossify, it is also the only long bone that ossify by intramembranous ossification (*Ogata and Uthoff, 1990*). The clavicle consists of cancellous bone, enveloped by cortical bone, which is much thicker in the middle 35% of the clavicle than in the lateral and medial fifths (*Andermahr, 2007*).

The clavicle serves as the sole bone connecting the axial skeleton to the shoulder girdle through the sternoclavicular joint medially and the acromioclavicular joint laterally. It transmits the weight of the upper limb to the axial skeleton. Its unique and complex shape plays an important role in the stability, movement and cosmetic aspect of the shoulder girdle (*Anderson 2003*).

The shaft of the clavicle is gently curved and its shape resembles the italic f letter, being convex forwards in its medial two thirds and concave forwards in its lateral third (*Standring, 2005*).

The clavicle is the most frequently fractured bone in human skeleton, Most of the fractures occur in the shaft of the clavicle which is accordingly the weakest part of the bone (*Anderson, 2003*).

Historically, midclavicular fractures were treated non-operatively using slings or figure 8 braces, which have a higher rate of either non-union or malunion resulting in shoulder complications (*Stanley et al., 1988*); (*Hill et al., 1997*); (*Jubel et al., 2003*). Clavicular non-union or malunion influences the architecture of

the whole shoulder girdle and the coordination between its elements (*Andermahr et al., 2006*).

Recent studies have shown that the operative treatment have superior results over non-operative treatment (*Mckee et al., 2006*). There are two approaches for operative treatment; external fixation or internal fixation. External fixation using plate and screw may be cosmetically displeasing, uncomfortable and irritating for many patients (*Wenninger et al., 2013*). On the other hand, internal fixation of the clavicle using intramedullary nail is accompanied by a higher rate of cure and lesser complications and is largely considered as the treatment of choice (*Jubel et al., 2003*); (*Wenninger et al., 2013*).

Although intramedullary fixation is an effective mode of treatment (*King and Ikram, 2011*); (*Ferran et al., 2010*); (*Houwert et al., 2012*); (*Liu et al., 2010*), the shape and size of the medullary canal of the clavicle can be a prohibiting factor for the use of intramedullary nail, making the placement of intramedullary devices difficult. If the canal is too small to allow reamers or nails to be inserted, the fixation of the fracture by means of an intramedullary device is impossible. Again absence of an adequate medullary canal at the far medial and lateral sides of the clavicle, causes problems while passing the intramedullary device far enough past the fracture site to give adequate fracture stability (*King and Ikram, 2011*). Hence it is important to accurately determine the size of the medullary canal of the clavicle before considering intramedullary fixation.

#### **AIM OF WORK**

---

The present work was designed to study the length, the curvatures as well as the dimensions of the medullary canal of the clavicle among Egyptians using three dimensional computed tomography. The study help to verify whether the anatomy of the clavicle and its medullary canal is suitable for intramedullary fixation in treatment of clavicular fractures.

#### **MATERIAL AND METHODS**

---

This study was carried on one hundred clavicles belonging to fifty subjects divided

equally into twenty five male and twenty five female and aging between 2060- years.

Subjects were randomly selected from the patients coming to perform computerized tomography scanning of their chest for different clinical presentation. Patients with congenital malformations of the clavicle, previous fracture or previous surgery of the clavicle were excluded from this study.

- The Device used is Multidetector Computed Tomography 16 detector Toshiba Asteon.
- The patients scanned in the supine position with the arm above the head. Antero-posterior and lateral scanograms were performed.
- The patients were scanned from the level just above the acromion process till the middle of the chest.
- The images were obtained in the axial plane with post processing coronal and sagittal reconstruction.
- Multislice CT scan of the chest with coronal and sagittal reformatting and 3D reconstruction of the clavicle was done; (*Bernat et al., 2014*); (*King et al., 2014*); (*Mathieu et al., 2014*).
- Measurements were taken on the 3D images in cranial view to assess the length of the clavicle using the point tracing method (defined as the line which crosses through the center of the clavicle). (Fig. 1)
- Measurements were taken on the 3D images in cranial view to assess the angle between the sternoclavicular end and the shaft (medial angle also called the sternal angle) and the angle between the acromioclavicular end and the shaft (lateral angle also called the acromial angle). The angles were measured by obtaining the angle between two lines drawn tangential to the shaft of the bone (Fig. 2)
- Measurements were taken on the coronal section images to determine the cross sectional dimensions (height and width) of the medullary canal of the clavicle in 3

reference points; in the most medial part, middle part and the most lateral part of the medullary canal .

- The height of the medullary canal was measured by drawing a vertical line that passes from the superior to the inferior limit of the canal in the three reference points (the most medial end, middle part and the most lateral end). (Fig. 3)
- The width of the medullary canal was measured by drawing a line that passes horizontally from side to side inside the canal in the three reference points (the most medial end, middle part and the most lateral end). (Fig. 4)
- Measurements were taken in the axial images to assess the length of the medullary canal; by subtracting the sum of the length at which the canal begins and ends from the total length of the clavicle. (Figs. 5, 6)

## RESULTS

---

The measurements of different parameters of the right and left clavicles were as follows.

### *Length of the clavicle: (Graph 1)*

**In males:** The mean length of the right clavicle was  $160.121.9 \pm$  mm and that of the left clavicle was  $162.515.5 \pm$  mm.

**In females:** The mean length of the right clavicle was  $155.619.7 \pm$  mm and that of the left clavicle was  $160.319.6 \pm$  mm.

### *Medial angle of clavicle: (Graph 2)*

**In males:** The mean medial angle of the right clavicle was  $160.2 \pm 5.9^\circ$  and the mean medial angle of the left clavicle was  $160.4 \text{ degrees} \pm 8^\circ$

**In females:** The mean medial angle of the right clavicle was  $156.3 \pm 5.2^\circ$  and the mean medial angle of the left clavicle was  $157.2 \pm 5.2^\circ$ .

### *Lateral angle of the clavicle: (Graph 3)*

**In males:** The mean of the lateral angle of the right clavicle was  $147.3 \pm 8.3^\circ$  and the mean of the lateral angle of the left clavicle was  $152.7 \pm 8^\circ$

**In females:** The mean of the lateral angle of the right clavicle was  $148.1 \pm 12.7^\circ$  and the mean of the lateral angle of the left clavicle was  $154.6 \pm 9.5^\circ$

### *Height of medullary canal at the medial end of the clavicle: (Graph 4)*

**In males:** The mean of the height of medullary canal in the right clavicle was  $10.09 \pm 2.8$  mm and that of the left clavicle was  $10.12 \pm 2.7$  mm.

**In females:** The mean of the height of medullary canal in the right clavicle was  $7.2 \pm 3.2$  mm and that of the left clavicle was  $7.5 \pm 3.1$ mm.

### *Width of medullary canal at the medial end of the clavicle: (Graph 5)*

**In males:** The mean of the width of medullary canal at the medial end of the right clavicle was  $10.6 \pm 2.5$  mm and that of the left clavicle was  $10.9 \pm 2.1$  mm.

**In females:** The mean of the width of medullary canal at the medial end of the right clavicle was  $7.8 \pm 2.6$  mm and that of the left clavicle was  $7.6 \pm 2.2$  mm.

### *Height of the medullary canal at the middle part of the clavicle: (Graph 6)*

**In male:** The mean of the height of the medullary canal at the middle part of the right clavicle was  $6.4 \pm 2.2$  mm and that of the left clavicle was  $6.6 \pm 2$  mm.

**In females:** The mean of the height of the medullary canal at the middle part of the right clavicle was  $4.7 \pm 2.2$  mm and that of the left clavicle was  $4.8 \pm 2.2$  mm.

### *Width of the medullary canal at the middle part of the clavicle: (Graph 7)*

**In males:** The mean of the width of the medullary canal at the middle part of the right clavicle was  $6.6 \pm 2.3$  mm and that of the left clavicle was  $6.6 \pm 2.1$  mm.

**In females:** The mean of the width of the medullary canal at the middle part of the right

clavicle was  $4.2 \pm 0.9$  mm and that of the left clavicle was  $4.5 \pm 1.4$  mm.

**Height of the medullary canal at the lateral end of the clavicle: (Graph 8)**

**In males:** The mean of the height of the medullary canal at the lateral end of the right clavicle was  $7.7 \pm 2.1$  mm and that of the left clavicle was  $7.4 \pm 2$  mm.

**In females:** The mean of the height of the medullary canal at the lateral end of the right clavicle was  $5.8 \pm 2.5$  mm and that of the left clavicle was  $5.3 \pm 2.2$  mm.

Width of the medullary canal at the lateral end of the clavicle: (Graph 9)

**In males:** The mean of the width of the medullary canal at the lateral end of the right clavicle was  $7.8 \pm 2.3$  mm and that of the left clavicle was  $7.9 \pm 2.8$  mm.

**In females:** The mean of the width of the medullary canal at the lateral end of the right clavicle was  $4.9 \pm 2.6$  mm and that of the left clavicle was  $4.8 \pm 2.2$  mm.

**Start of the medullary canal at the sternal end of the clavicle: (Graph 10)**

**In males:** The mean length at which the canal start was  $4.9 \pm 0.8$  mm from the sternal end in right clavicle and that of the left clavicle was  $5.3 \pm 1$  mm from the sternal end.

**In females:** The mean length at which the canal start was  $4.6 \pm 1.5$  mm from the sternal end in right clavicle and that of the left clavicle was  $4.51.5 \pm$  mm from the sternal end.

**End of the medullary canal at the acromial end of the clavicle: (Graph 11)**

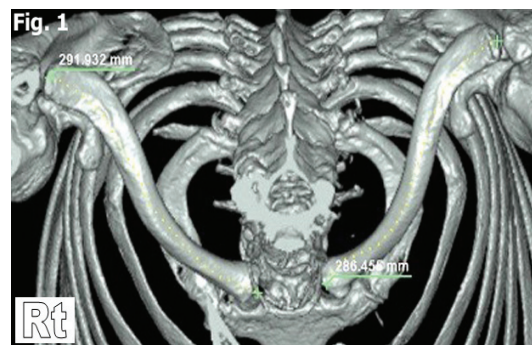
**In males:** The mean of the length at which the medullary canal ends from the acromial end in right clavicle was  $6.171.5 \pm$  mm and that of the left clavicle was  $5.7 \pm 1.2$  mm.

**In females:** The mean of the length at which the medullary canal ends from the acromial end in right clavicle was  $4.81.3 \pm$  mm and that of the left clavicle was  $5 \pm 1.9$  mm.

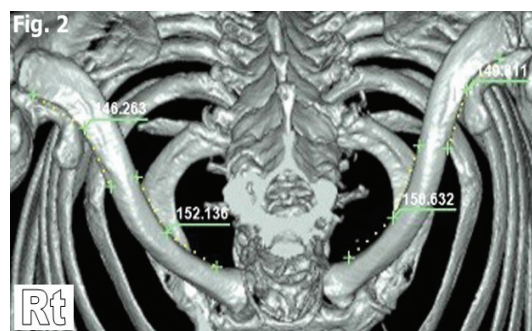
**Length of the medullary canal: (Graph 12)**

**In males:** The mean length of the medullary canal in right clavicle was  $148.7 \pm 21.4$  mm and that of the left clavicle was  $151.3 \pm 15.6$  mm.

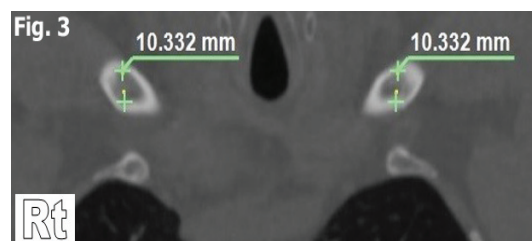
**In females:** The mean length of the medullary canal in right clavicle was  $146.2 \pm 19$  mm and that of the left clavicle was  $150.7 \pm 18.6$  mm.



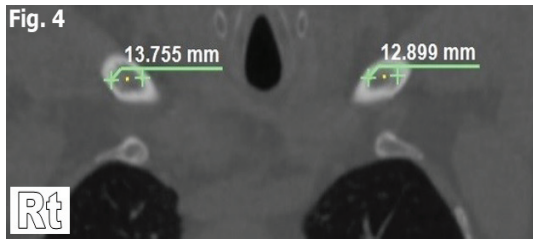
**Fig. 1:** A 3D computed tomography photo showing the measurement of the length of both clavicles using the point tracing method.



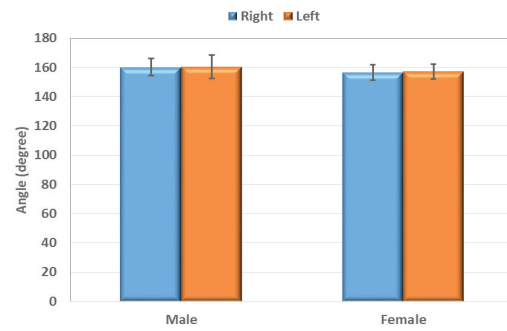
**Fig. 2:** A 3D computed tomography photo showing the measurements of the medial and lateral angles of both clavicles.



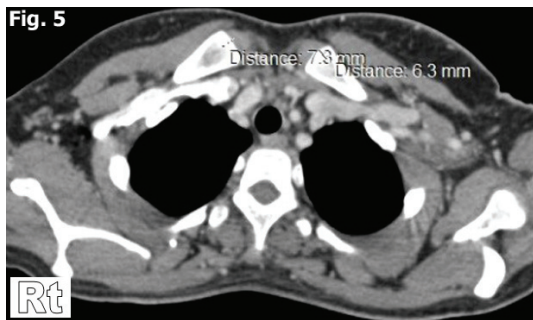
**Fig. 3:** A computed tomography photo (coronal section) showing how to measure the height of medullary canal of both clavicles.



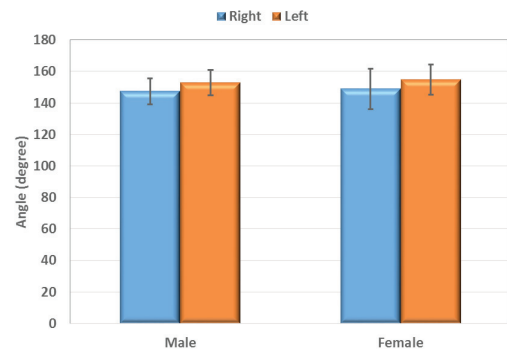
**Fig. 4:** A computed tomography photo (coronal section) showing how to measure the width of medullary canal of both clavicles.



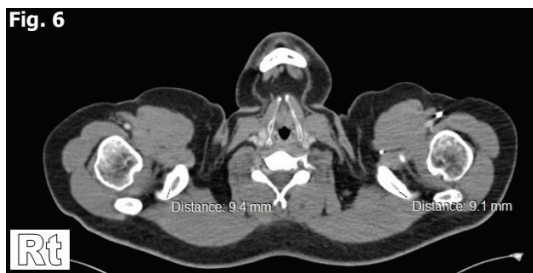**Graph 2:** Medial angle of right and left clavicle in both genders



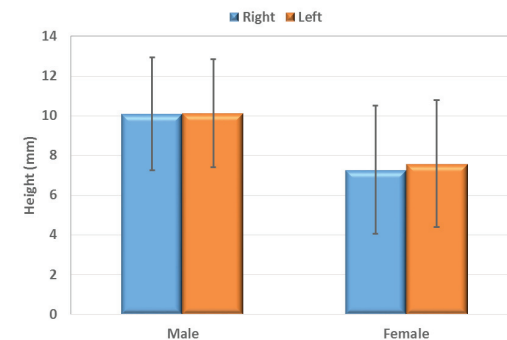
**Fig. 5:** A computed tomography photo (horizontal section) showing the measurements of the length at which the medullary canal begins.



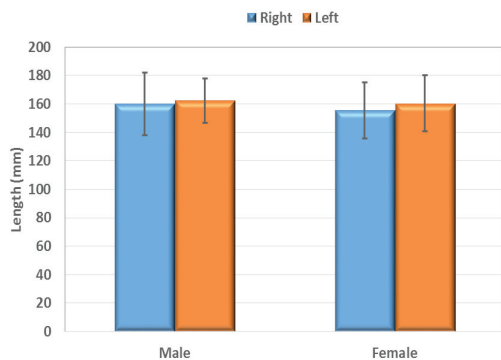
**Graph 3:** Lateral angle of right and left clavicle in both genders



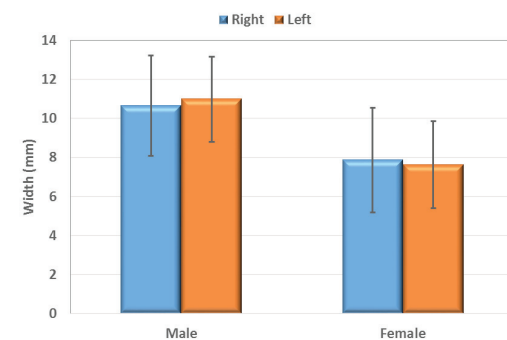
**Fig. 6:** A computed tomography photo (horizontal section) showing the measurements of the length at which the medullary canal ends.



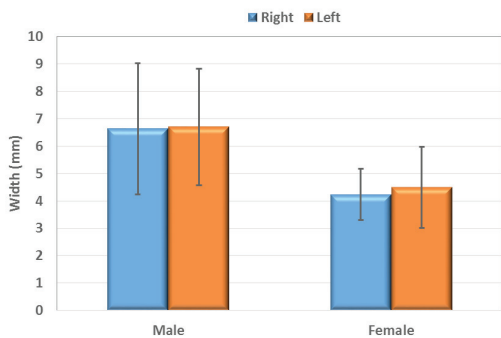
**Graph 4:** Height of medullary canal of medial end of right and left clavicle in both genders



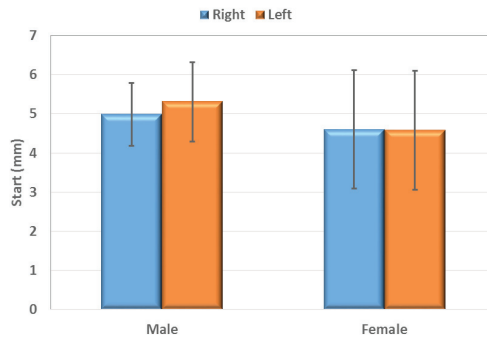
**Graph 1:** Length of right and left clavicle in both genders



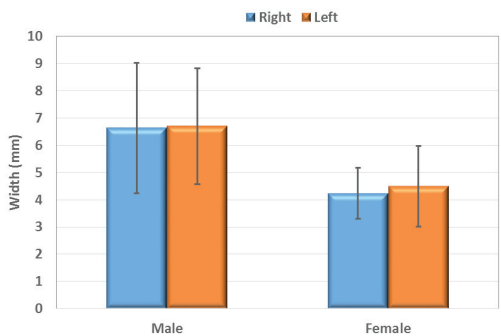
**Graph 5:** Width of medullary canal of medial end of right and left clavicle in both genders



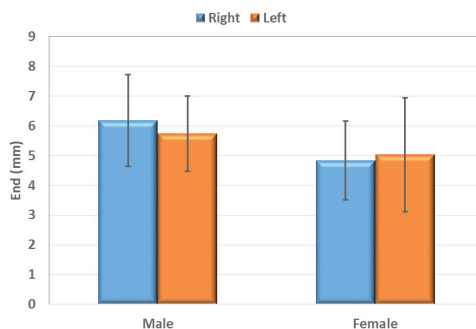
**Graph 6:** Height of middle part of medullary canal of right and left clavicle in both genders



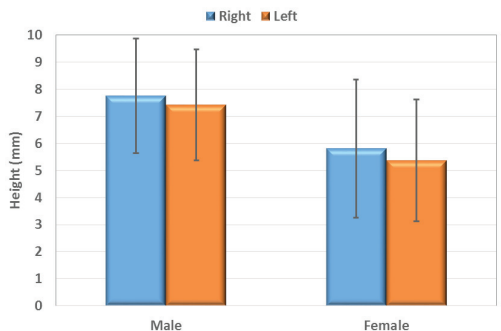
**Graph 10:** Start of medullary canal at the sternal end of right and left clavicle in both genders



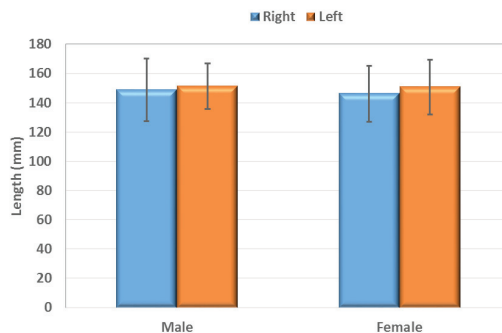
**Graph 7:** Width of middle part of medullary canal of right and left clavicle in both genders



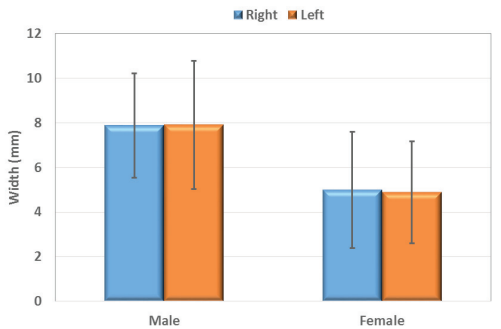
**Graph 11:** End of medullary canal at the acromial end of right and left clavicle in both genders



**Graph 8:** Height of medullary canal of lateral end of right and left clavicle in both genders



**Graph 12:** Length of medullary canal of right and left clavicle in both genders



**Graph 9:** Width of medullary canal of lateral end of right and left clavicle in both genders

## DISCUSSION

The human clavicle has a highly variable and complex bony anatomy that makes accurate study of its morphology a challenge. Literatures have pointed out that morphology of the clavicle shows a number of intra and inter-individual variations (Andermahr et al., 2007). These anatomical variations can make the use of fixation devices for the treatment of clavicle fractures challenging (Huang et al., 2007).

Although the anatomy of the clavicle has been widely studied using cadaver and bone bank specimens, computed tomography imaging has been shown to be an accurate method for describing the anatomy of the clavicle (*Sinha et al., 2011*). The dimensions of the clavicle and its canal were determined in living subjects avoiding possible post-mortem changes (*Galley et al., 2009*)

The CT scans with coronal and sagittal reformatting and 3D reconstruction were performed on one hundred clavicles belonging to fifty subjects. Measurements of different parameters of the clavicles were taken. Concerning the length of male clavicles was found to be generally longer than female clavicles. Again the length of the left clavicle was longer than that of the right clavicle in both sexes. This side difference might be attributed to hand dominance and different workloads of the respective upper limbs during growth (*Chavada et al., 2013*).

The other important point concerning the length of the clavicle observed in the current study was that the length of Egyptian clavicles were longer than those of the French clavicles (*Olivier, 1951*), Northwest Indians (*Kaur et al., 2002*) and South Indians (*Sudha, 2014*). This could be explained by racial or genetic factors. (*Chavada et al., 2013*) claimed that the variations in the length of the clavicle may be also related to the nutritional factors.

In the present study, the medial as well as the lateral angle of the left clavicle were greater than that of the right clavicle in both sexes, indicating that the curves of the right clavicle are greater than that of left clavicle which led to a shorter right clavicle as compared to the left one. Similar findings were reported by (*Haque et al., 2011*).

In the current work, the height and width of the medullary canal of the clavicle were generally greater in males than in females who have a relatively smaller canals. Again the height and width of the medial and lateral ends of the medullary canal were greater than the height and width of its mid-region. Hence the mid-region of the medullary canal is the narrowest part and the cross sectional area then gradually increase towards both the acromial and sternal ends.

The three dimensional anatomical studies can provide more information than the traditional two dimensional studies (*Daruwalla et al., 2010*). These information have a great importance when considering intramedullary nailing techniques (*Bachoura et al., 2013*), where common intraoperative and postoperative complications could be avoided by proper examination of the anatomy of the clavicle (*Andermahr et al., 2007*).

## CONCLUSION

---

Computed tomography imaging has shown to be an accurate method for describing the anatomy of the clavicle. Data could be used to determine whether the anatomy of the clavicle and its medullary canal are suitable for intramedullary fixation.

## REFERENCES

---

- Andermahr J, Jubel A, Elsner A (2007):** Anatomy of the clavicle and the intramedullary nailing of midclavicular fractures. *Clin Anat.*, 20(1):48-56.
- Andermahr, J.; Jubel, A.; Elsner, A.; Prokop, A.; Tsikaras, P.; Jupiter, J. and Koebke, J.(2006):** Malunion of the clavicle causes a significant glenoid malposition: A quantitative anatomic investigation. *Surg. Radiol. Anat.* 28:447-456
- Anderson, K. (2003):** Evaluation and treatment of distal clavicle fractures. *Clin Sports Med.*, 22:319-32.
- Bachoura, A.; Deane, A.S.; Wise, J.N. and Kamineni, S. (2013):** Clavicle morphometry revisited: a 3 dimensional study with relevance to operative fixation. *J Shoulder Elbow Surg.*, 22: 15-21.
- Bernat, A.; Huysmans, T.; Van Glabeek, F.; Sijbers, J.; Gielen, J. and Von Tongel, A. (2014):** The Anatomy of the clavicle: A three dimensional cadaveric study. *Clin. Anat.*, 27: 712-723.

**Chavada, H.S.; Khatri, C.R.; Varlekar, P.D. and Saiyad, S.S. (2013):** Morphometric analysis and sex determination from clavicles in Gujara population. *NJIRM.*, 4(6): 18-22.

**Daruwalla, Z.; Courtis, P.; Fitzpatrick, D. and Mullet, H. (2010):** Anatomic variation of the clavicle: a novel 3-dimensional study. *Clin. Anat.*, 23:199-209.

**Ferran N, Hodgson P, Vannet N, Williams R, Evans R (2010):** Locked intramedullary fixation versus plating for displaced and shortened midshaft clavicle fractures: a randomized clinical trial. *J Should Elb Surg* 19:783–789.

**Galley I, Watts A, Bain G (2009):** The anatomic relationship of the axillary artery and vein to the clavicle: a cadaveric study. *J Shoulder Elbow Surg* 18(5):21–25.

**Haque, M.K.; Mansur, D.I. and Sharma, K. (2011):** Study of curvatures of clavicle with its clinical importance. *Kathmandu Univ. Med. J.*, 36(4):279-282.

**Hill, J.M.; McGuire, M.H. and Crosby, L.A. (1997):** Closed treatment of displaced middle third fractures of the clavicle gives poor results. *J. Bone Joint Surg.*, Br 79B:537-539.

**Houwert R, Wijdicks F, Steins Bisschop C, Verleisdonk E, Kruyt M (2012):** Plate fixation versus intramedullary fixation for displaced mid-shaft clavicle fractures: a systematic review. *Int Orthop* 36(3):579–585.

**Huang JI, Toogood P, Chen MR, Wilber JH, Cooperman DR (2007):** Clavicular anatomy and the applicability of precontoured plates. *J Bone Joint Surg Am* 89(10):2260.

**Jubel, A.; Andermahr, J.; Bergmann, H.; Prokop, A. and Rehm, K. (2003):** Elastic stable intramedullary nailing of midclavicular fractures in athletes. *Br. J. Sports Med.*, 37:480-483.

**Kaur, H.; Harjeet.; Sahni, D. and Jit, I. (2002):** Length and curves of the clavicle in Northwest Indians. *J. Anat. Soc. India*, 51(2):199-209.

**King PR and Ikram A (2011):** Intramedullary locked fixation of middle third clavicle fractures-a review of early results. *SA orthop J* 10(4):67–74.

**King, P.R.; Scheepers, S. and Ikram, A. (2014):** Anatomy of the clavicle and its medullary canal: a computed tomography study. *Eur. J. Orthop. Surg. Traumtol.*, 24(1): 37-42.

**Liu H, Chang C, Chia W, Chen C, Tarng Y, Wong C (2010):** Comparison of plates versus intramedullary nails for fixation of displaced midshaft clavicular fractures. *J Trauma* 69(6):82–87.

**Mathieu, P.A.; Marcheix, P.S.; Hummel, V.; Valliex, D. and Mabit, C. (2014):** Anatomical study of the clavicle: endomedullary morphology. *Surg. Radiol. Anat.*, 36(1):11-15.

**Mckee, M.D.; Pederson, E.M.; Jones, C., Stephen, D.J.; Kreder, H. J.; Et al., (2006):** Deficits following nonoperative treatment of displaced midshaft clavicular fractures. *J. Bone Joint Surg. Am.*, 88: 35-40.

**Ogata, S. and Uhthoff, H. K. (1990):** The early development and ossification of the human clavicle, An embryologic study. *Acta Orthop. Scand.*, 61(4):330-334.

**Olivier, G. (1951):** Anthropologie de la clavicule III, La Clavicule due Francis. *Bulltins et. Memories de la soc. D’ Anthro.*, 2:121-157. Quoted from Kaur, H.; Harjeet.; Sahni, D. and Jit, I. (2002): Length and curves of the clavicle in Northwest Indians. *J. Anat. Soc. India*, 51(2):199-209.

**Sinha, A.; Edwin, J.; Sreeharsha, B.; Bhalai, V. and Brownson, P. (2011):** A radiologic study to define safe zones for drilling during plating of clavicle fractures. *J. Bone Joint Surg.*, Br 93(9):1247-1252.

**Standring, S. (2005):** The anatomical basis of clinical practice Gray’s anatomy 39<sup>th</sup> edition. Elsevier Churchill Livingstone. London, 817-819.



**Stanley, D.; Trowbridge, E.A. and Norris, S.H. (1988):** Recovery following fractures of the clavicle treated conservatively. *Injury*, 19:162-164.

**Sudha, R. (2014):** Study of clavicle: length and curvatures in South Indian population. *Nat. J.Clin.Anat.*, 3(4): 198-202.

**Weninger, J.J.; P.A.-C.; Dannenbaum, J.H.; Branstetter, J.G. and Arrington, E.D. (2013):** Comparison of Complication rates of intramedullary pin fixation versus plating of midshaft clavicle fractures in an active duty military population. *J. Surg. Orthop. Advan.*, 22(1):77-81.

## تقوسات عظمة الترقوه وتجويفها النخاعي في المصريين: دراسة ثلاثية الابعاد باستخدام الأشعة المقطعية

ا.د. نبيلة اديب عبد المسيح، د. محمد حافظ شعبان، د. مجدي فؤاد يواقيم،  
ط. مريم عاطف فهيم

قسم التشريح و علم الاجنة، كلية الطب، جامعة القاهرة

### ملخص البحث

**المقدمة:** تعد عظمة الترقوه من اكثر العظام تعرضا للكسر في الهيكل العظمي. الكسور التي تعالج بأسلوب غير جراحى تحمل احتمال اعلى لعدم الالتئام او الالتئام الخاطى. التعامل الجراحى مع الكسر يعطى نتائج اعلى من التعامل غير الجراحى و يكون بالثبتيب الخارجى او الثبتيب الداخلى. الثبتيب الخارجى غير مريح و له اثار تجميلية غير مرغوب فيها. اما الثبتيب الداخلى للكسر فله نتائج افضل و مضاعفات اقل و لكن شكل و حجم التجويف النخاعى يعتبر عامل هام فى نجاح تركيب مسمار الثبتيب الداخلى.

**الهدف من البحث:** قد تم تصميم هذا البحث لدراسه تقوسات عظمة الترقوه و تجويفها النخاعي من اجل دراسه الميزات المورفولوجية للترقوه بين المصريين و للتحقق ما اذا كانت الترقوه و تجويفها النخاعي قابلة للتسمير النخاعي في حالات كسر العظمه ام لا .

**الطرق والمواد المستخدمه:** تمت الدراسه على مائة ترقوه باستخدام الاشعة المقطعية ثلاثية الابعاد مع عمل مقاطع تاجيه وطوليه لمرضى لمرضى لا يعانون من مشاكل طبيه فى عظمه الترقوه.

**النتائج:** فيما يتعلق بطول عظمة الترقوه لوحظ ان الترقوه عند الذكور اطول منها عند الاناث، و كانت الترقوه اليسرى اطول من اليمنى في كلا الجنسين. اما عن الزاويه الانسية و الجانبية فقد كانا اكبر على الجانب الايسر في الذكور و الاناث. أما فيما يتعلق بابعاد القناة النخاعية للترقوه فقد كانت الابعاد عند الذكور اكبر منها عند الاناث .

**الخلاصة:** الاشعه المقطعيه لها دور اساسى لتقييم ابعاد و تقوسات عظمه الترقوه و تجويفها النخاعي لبيان امكانيه تركيب مسمار نخاعى للثبتيب الداخلى لكسور عظمه الترقوه.

**مفاتيح الكلمات:** تقوسات عظمة الترقوه – تجويف نخاعى الاشعة - المقطعية.