

DUODENO-JEJUNAL JUNCTION : IS IT AN ANATOMICAL SPHINCTER ?

George F. B. Hanna, Abeer E. Abaskharoun and Rana A. El - Beshbishy
Anatomy Department, Faculty of Medicine, Ain Shams University

INTRODUCTION

The duodenum is not a mere passage of food coming from the stomach (Saenko et al., 1990 - a), but there is a well - known functional relationship between the pylorus and the duodeno - jejunal junction (DJJ) (Saenko et al., 1990 - b). It has been established that evacuation of the duodenum was normally submitted to exponential law and depended on absolute quantity of food evacuated from the stomach (Saenko et al., 1989 - b). Moreover, optimal conditions for duodenal alimentation were reported to depend on the coordinated activity of the stomach and duodenum (Kerlin et al., 1982; Quigley, 1987). Such coordination may result from synchronous activity of the pyloric sphincter and the DJJ. Whereas the activity of the pyloric sphincter was well described in the literature, information about the DJJ was limited to external morphologic characteristics (Repcuic and Campeanu, 1981; Zypen and Reves, 1984). It has been suggested that the Treitz ligament, an important part of the DJJ, determined the opening of the DJJ angle, thus facilitating the emptying of the duodenal content into the jejunum (Repcuic and Campeanu, 1981). Furthermore, the functional role of the Treitz ligament as an active regulator of solid food evacuation from the duodenum was studied (Saenko et al., 1989 - b). As regards the DJJ, it has been postulated that the DJJ was probably a "functional" sphincter that provided coordinated activity of the stomach and duodenum (Read et al., 1980; Virchenko et al., 1993). The DJJ was also considered, in addition to the Treitz ligament, as a valve that regulated the duodenal content emptying (Saenko et al., 1989 - a; Saenko et al., 1990 - a). To our knowledge, very little information, if any, dealt with the possibility of existence of an "anatomical" sphincter at the DJJ. The present study was then undertaken to investigate that hypothesis, providing more coordinated activity of the stomach and duodenum, thus serving as one of the

factors regulating the process of digestion and absorption of nutrients from the duodenum.

MATERIAL AND METHODS

Thirty adult albino rats of Sprague - Dawley strain (250 - 350 gm) were used in the present study. All animals were obtained from the animal house of Faculty of Medicine, Ain Shams University, and were sacrificed with an overdose of ether. The anterior abdominal wall of each animal was incised, and the DJJ was identified and extracted. Longitudinal as well as serial transverse sections at multiple levels were taken in the DJJ. The sections were fixed in 10% neutral buffered formaline, and processed for 5 μ m thick paraffin sections. The paraffin sections were stained with haematoxylin and eosin (Hx. & E.) (Drury and Wallington, 1980), Masson's trichrome (Masson's, 1929), and modified Bielschowsky technique of silver stain (Kiernan, 1999), and were then examined with the light microscope. For each : duodenum, jejunum, and duodenojejunal junction, successive pictures were captured to include all the layers from mucosa to muscularis externa. Pictures were then scanned and photographic montage was done by Adobe Photoshop software to reconstruct the three regions studied. That procedure allowed better comparison between all the layers in each region.

RESULTS

In all sections, starting from the duodenum, the DJJ was identified by the absence, following a gradual decrease, of the Brunner's glands in the duodenal submucosa.

Starting from the duodenum, histological examination of the longitudinal paraffin sections revealed that mucosal folding increased at the DJJ (Fig. 1). Moreover, a markedly prominent muscularis mucosa (Fig. 2) was observed to margin the intestinal glands at the DJJ. In silver stained sections, numerous nerve cells between the mucosal glands (Fig. 3), as well as nerve fibers in the vicinity of the prominent muscularis mucosa (Figs. 4, 5) were seen.

Furthermore, the submucosa of the DJJ was highly vascular (Figs. 6, 7). It was noticed to contain a large number of blood vessels, a feature not seen in the duodenal or the jejunal submucosa. Examination of the sections stained by Masson's trichrome stain revealed that the submucosa of the DJJ also contained many

collagenous fibers (Figs. 7, 8). In addition, the DJJ submucosa exhibited a greater innervation than that of the duodenum or jejunum. Numerous nerve cells (Fig. 9) and nerve fibers (Fig. 10) could be easily seen in sections stained with silver. The observed nerve cells were observed to have vesicular nuclei (Fig. 11).

Careful examination of longitudinal and transverse serial paraffin sections of the DJJ revealed marked thickening of the muscularis externa (Fig. 12). That thickening was markedly observed in the inner circular layer of the DJJ (Figs. 8, 13). Moreover, increased density of nerve cells was observed near the markedly thickened inner circular layer of the muscularis externa (Figs. 14, 15). The observed nerve cells were sometimes arranged in rows (Fig. 16), and presented vesicular nuclei (Figs. 17, 18). In addition, large blood vessels were observed within the thickened inner circular layer of the muscularis externa (Figs. 6, 18).

Computerized reconstruction and montage of successive scanned Masson's stained photomicrographs of the duodenum, DJJ, and jejunum allowed better comparison of the three regions. In the duodenum (Fig. 19), relative decrease in mucosal folding and ill-defined muscularis mucosa were noticed. Moreover, relative low content of collagenous fibers was seen in the duodenal submucosa that also showed the presence of Brunner's glands. Lastly, the duodenal muscularis externa was smaller in thickness than that of the DJJ. At the DJJ (Fig. 20), there was a relative increase in mucosal folding, a markedly prominent muscularis mucosa, highly vascular submucosa that was also rich in collagenous fibers, as well as markedly thickened inner circular layer of the muscularis externa. Finally in the jejunum (Fig. 21), less prominent muscularis mucosa, less vascular submucosa with less content of collagenous fibers, and not thickened muscularis externa were observed.

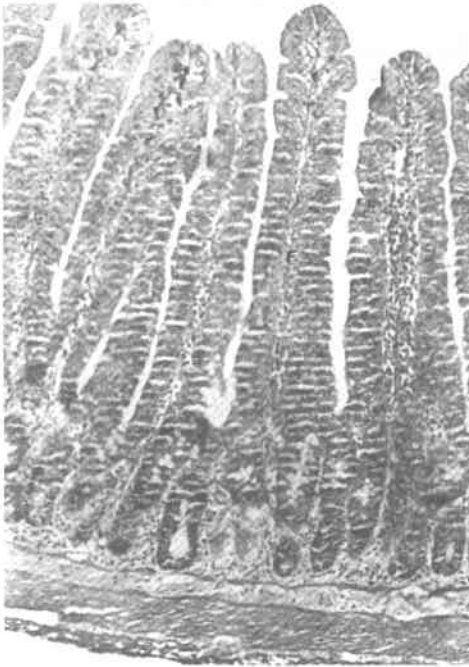

Fig. (1) : A photomicrograph of a transverse section of the DJJ showing an increase in the mucosal folding (F).
(Hx. & E.; x 100)

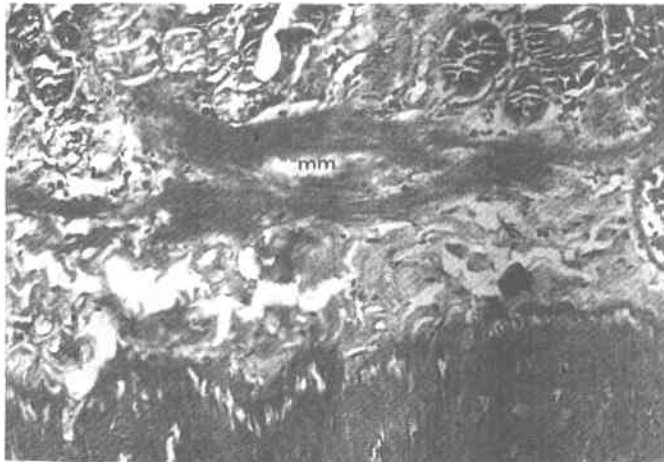


Fig. (2) : A photomicrograph of a longitudinal section of the DJJ showing a markedly prominent muscularis mucosa (mm) that was observed to margin the intestinal glands (G).
(Hx. & E.; x 200)

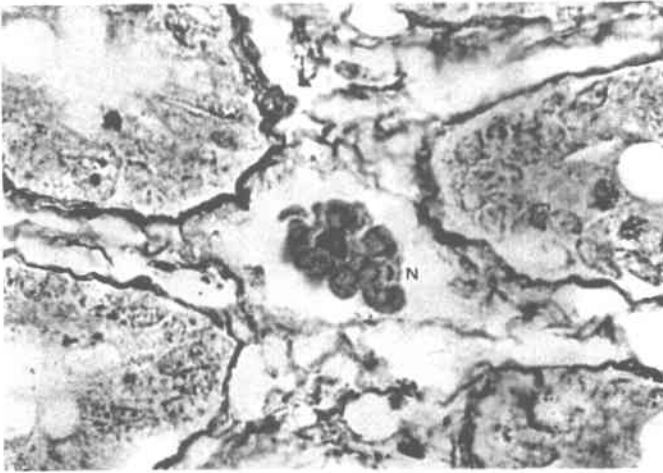


Fig. (3) :A photomicrograph of a longitudinal section of the DJJ showing numerous nerve cells (N) between the mucosal glands.
(Modified Bielschowsky Silver, x 400)

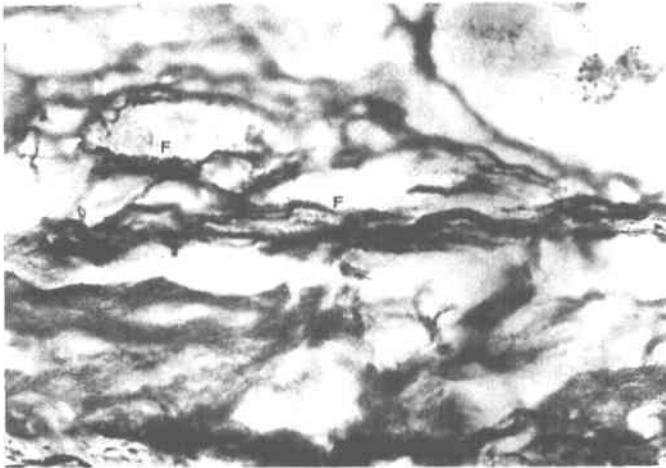


Fig. (4) :A photomicrograph of a longitudinal section of the DJJ showing numerous mucosal nerve fibers (F) in the vicinity of the prominent muscularis mucosa.
(Modified Bielschowsky Silver, x 1000)

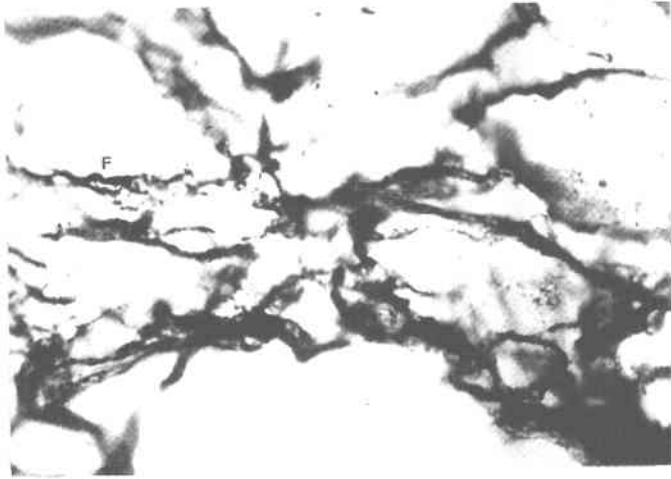


Fig. (5) : A photomicrograph of a longitudinal section of the DJJ showing numerous mucosal nerve fibers (F) in the vicinity of the prominent muscularis mucosa.

(Modified Bielschowsky Silver, x 1000)

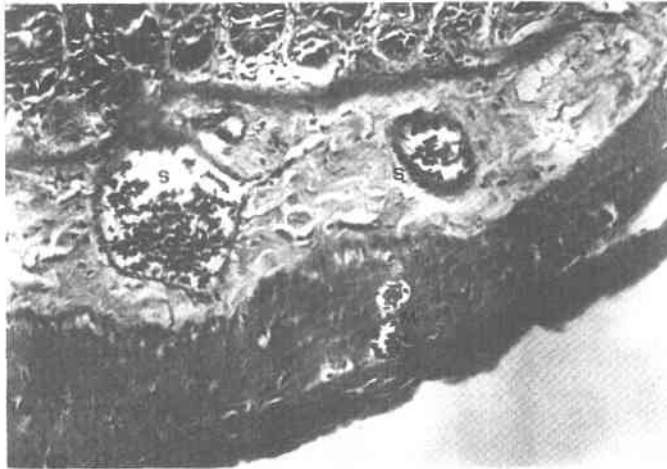

Fig. (6) : A photomicrograph of a longitudinal section of the DJJ showing multiple large dilated blood vessels in the submucosa (S) and the muscularis externa (M).

(Hx. & E.; x 200)

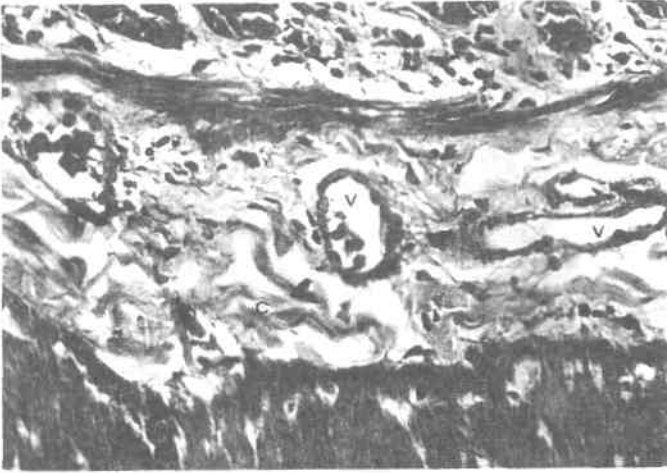

Fig. (7) : A photomicrograph of a longitudinal section of the DJJ showing multiple large dilated blood vessels (V) and a high content of collagenous fibers (C) in the submucosa.

(Masson's stain, x 400)



Fig. (8) : A photomicrograph of a longitudinal section of the DJJ showing a high content of collagenous fibers (C) in the submucosa and markedly thickened inner circular layer (M) of the muscularis externa.

(Masson's stain; x 400)

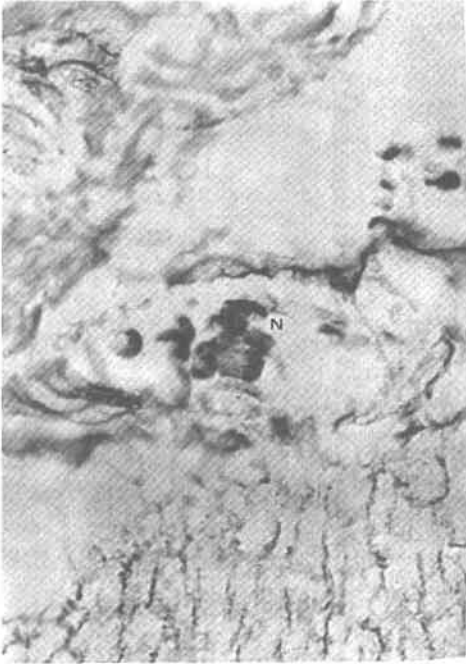

Fig. (9) :A photomicrograph of a longitudinal section of the DJJ showing many nerve cells (N) in the submucosa.
(Modified Bielschowsky Silver, x 400)

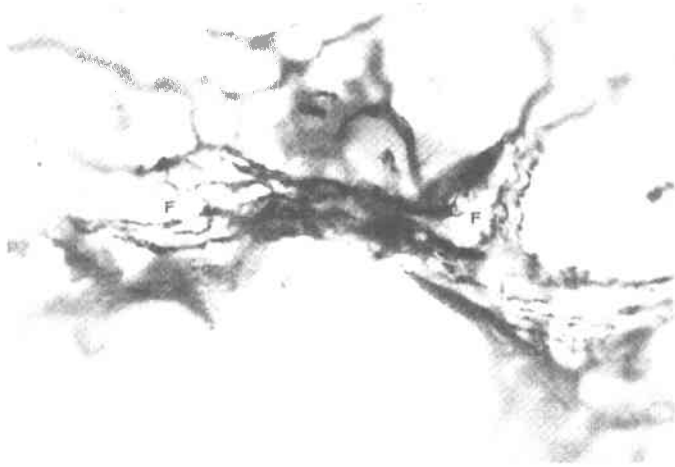


Fig. (10) :A photomicrograph of a longitudinal section of the DJJ showing numerous nerve fibers (F) in the submucosa.
(Modified Bielschowsky Silver, x 400)

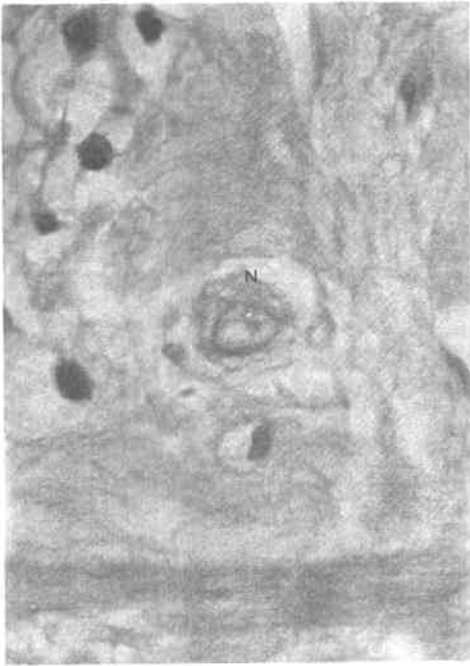


Fig. (11) :A photomicrograph of a transverse section of the DJJ showing a submucosal nerve cell (N) with a vesicular nucleus.

(Hx. & E.; x 1000)

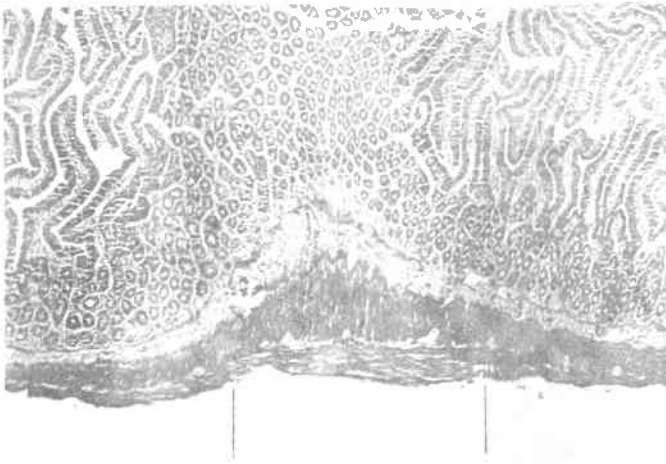


Fig. (12) :A photomicrograph of a longitudinal section of the DJJ (in the middle) showing marked thickening of the muscularis externa as compared to the duodenum (to the left) and the jejunum (to the right).

(Hx. & E.; x 40)

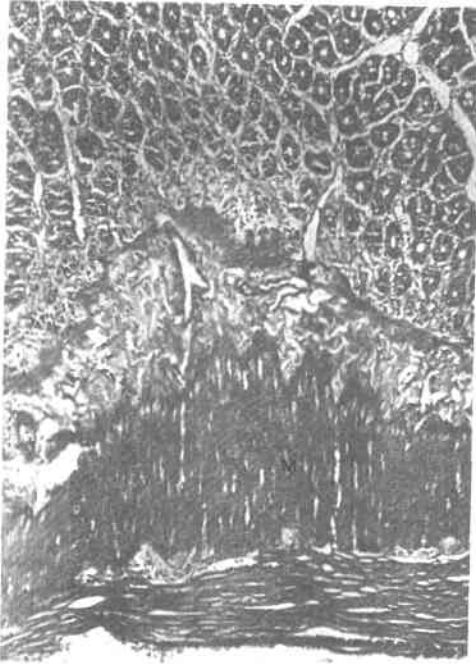


Fig. (13) :A higher magnification of the previous section showing the markedly thickened inner circular layer (M) of the muscularis externa.

(Hx. & E.; x 100)

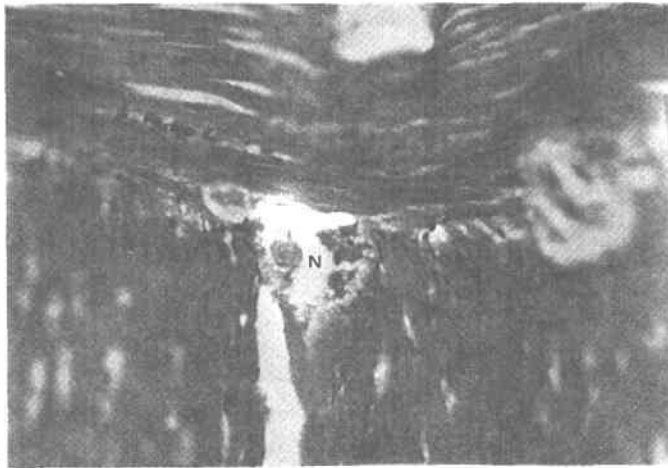


Fig. (14) :A photomicrograph of a longitudinal section of the DJJ showing nerve cells (N) near the markedly thickened inner circular layer of the muscularis externa.

(Hx. & E.; x 400)

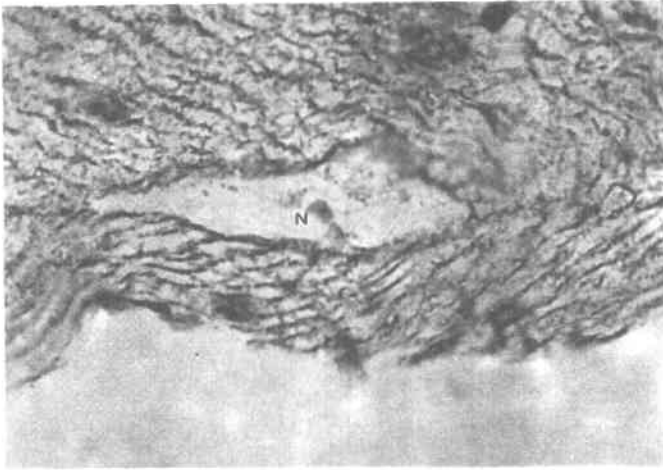


Fig. (15) : A photomicrograph of a longitudinal section of the DJJ showing nerve cells (N) near the markedly thickened inner circular layer of the muscularis externa.

(Modified Bielschowsky Silver, x 1000)

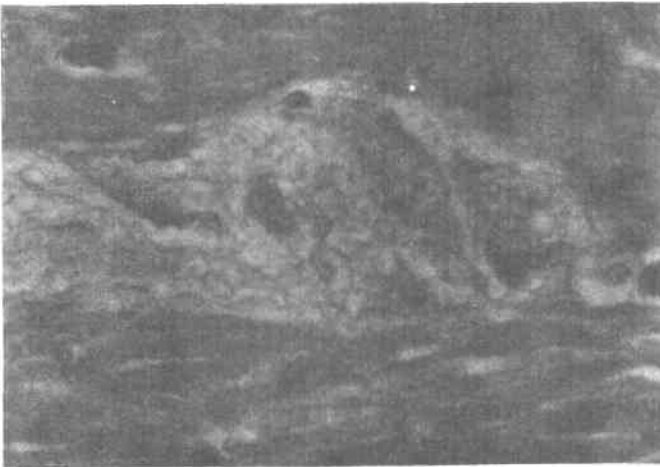

Fig. (16) : A photomicrograph of a transverse section of the DJJ showing that the nerve cells located near the markedly thickened inner circular layer of the muscularis externa were arranged in rows and presented vesicular nuclei.

(Hx. & E.; x 1000)

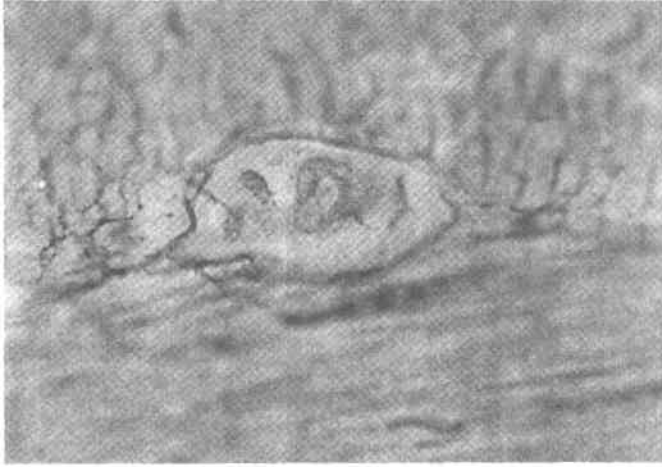


Fig. (17) : A photomicrograph of a transverse section of the DJJ showing that the nerve cells located near the markedly thickened inner circular layer of the muscularis externa were arranged in rows and presented vesicular nuclei.

(Modified Bielschowsky Silver, x 1000)

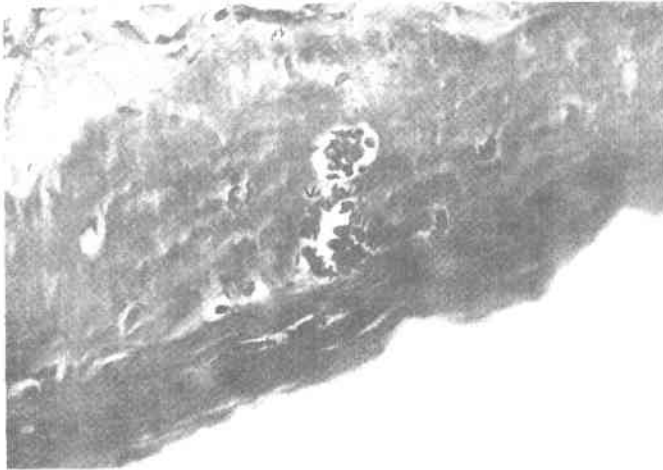

Fig. (18) : Another field of Fig. 6 showing large dilated blood vessels (V) in the muscularis externa.

(Hx. & E.; x 200)

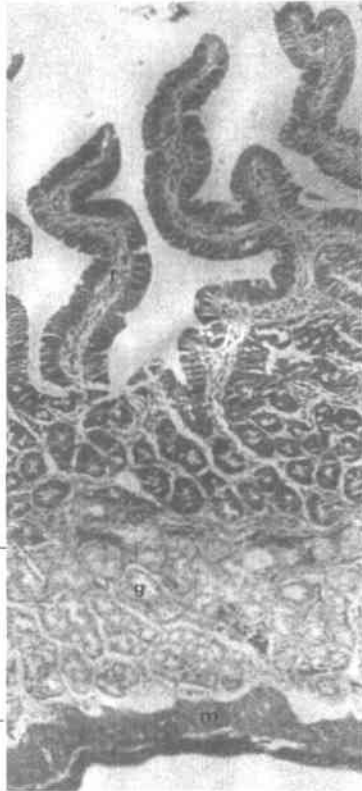

Fig. (19) :Computerized reconstruction and montage of successive scanned photomicrographs of the duodenum showing a relative decrease in mucosal folding (f), ill-defined muscularis mucosa, relative low content of collagenous fibers in the duodenal submucosa that also showed many Brunner's glands (g), and not thickened muscularis externa (m).
(Masson's stain, x 100)

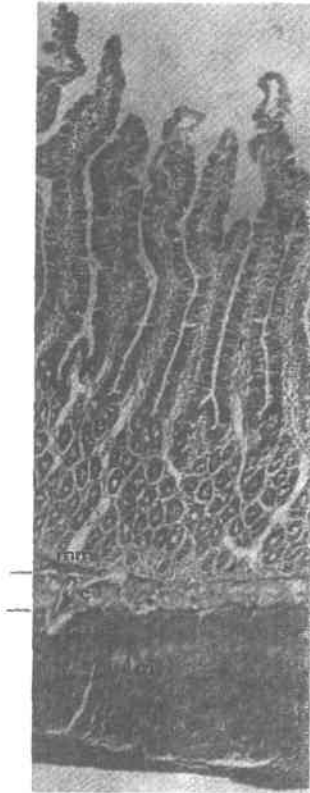


Fig. (20) :Computerized reconstruction and montage of successive scanned photomicrographs of the DIJ showing a relative increase in mucosal folding (f), a markedly prominent muscularis mucosa (mm), highly vascular submucosa that was also rich in collagenous fibers (c), as well as markedly thickened inner circular layer (m) of the muscularis externa. (Masson's stain, x 100)

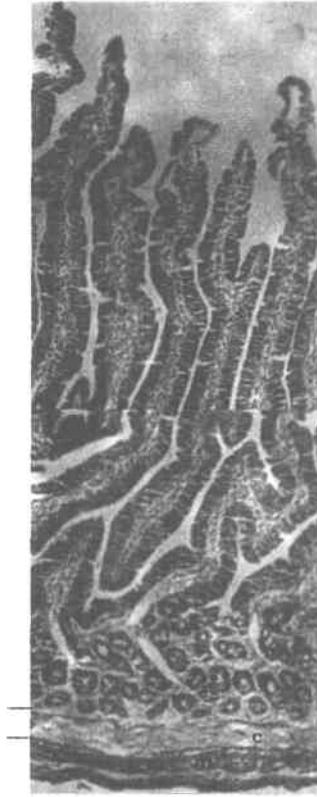


Fig. (21) :Computerized reconstruction and montage of successive scanned photomicrographs of the jejunum showing less prominent muscularis mucosa, less vascular submucosa with less content of collagenous fibers (c), and not thickened inner circular layer (m) of the muscularis externa.

(Masson's stain, x 100)

DISCUSSION

The histological findings of the present study of the DJJ may explain the physiological function of this region of the alimentary tract. The presence of a markedly folded mucosa at the DJJ noticed in the current work is thought to be due to a thicker underlying muscularis externa. The thickened muscle coat encroaches upon the submucosa, thus throwing the mucosa of the DJJ into many folds. That explanation is in accordance with a similar finding at the recto - sigmoid junction (Shafik et al., 1999). Functionally, since efficiency of absorptive and secretory processes was reported to be improved by increasing the surface area of contact between the mucosal epithelial cells and the intestinal lumen (Fawcett, 1994; Stevens and Lowe, 1997), the increased mucosal folds observed at the DJJ in the present study may play a role in enhancing the absorption of nutrients. That suggestion is in agreement with a similar one by Cormack (1987).

The current study further reported the presence of a prominent muscularis mucosa at the DJJ. That finding could be explained by the fact that the contractile activity of the prominent muscularis mucosa permits independent movement and folding of the mucosa increasing its contact with the food in the intestinal lumen (Junqueira et al., 1998; Kessel, 1998), thus aiding food digestion and absorption (Cormack, 1987). Moreover, since the contraction of the muscularis mucosa was stated to increase the height of the mucosal folds (Fawcett, 1994), it is conceivable that such changes in the surface topography of the mucosa may play a minor ancillary role in propelling and mixing the intestinal contents (Fawcett, 1994; Junqueira et al., 1998).

The most remarkable findings of the submucosa of the DJJ in the present investigation were its high vascularity, high content of collagenous fibers, and the presence of many nerve somata and nerve fibers. The excessive vascularity of the DJJ submucosa is thought to reflect increased muscular activity in the DJJ. That opinion is supported by Chuo (1982) who reported a correlation between increased blood flow and increased muscle tone. In that respect, the observed high submucosal vascularity may also be explained on the basis that those blood vessels nourish the small intestine and remove the products of digestion from that part of the alimentary tract. That view is in accordance with that of Junqueira et al. (1998).

Moreover, the present work also detected many collagenous fibers in the submucosa of the DJJ. Since the submucosa attaches the mucosa to the muscularis externa (Cormack, 1987), we believe that this finding matches with the marked

mucosal folding and the highly thickened inner circular layer of the muscularis externa reported in the present investigation, thus providing more support to the DJJ.

The current investigation showed a marked thickening of the inner circular, not the outer longitudinal, layer of the muscularis externa of the DJJ. That thickening seems to indicate the presence of an "anatomical" sphincter at the DJJ. Up to our knowledge, the present work is the first to report the existence of an anatomical sphincter at the DJJ. It is known that the basic muscle pattern of some areas of the gut is modified by a localized increase in the muscularis externa to act as an anatomical sphincter. This sphincteric localized thickening of the muscle coat was reported to occur in the inner circular, not the outer longitudinal, layer of the muscularis externa (Stevens and Lowe, 1997). That can be explained by the fact that the tone of the inner circular layer determines the overall luminal diameter of the intestine (Cormack, 1987), hence the contraction of the duodeno - jejunal sphincter may occlude its lumen thus preventing the passage of luminal contents to the jejunum (Stevens and Lowe, 1997). However, Repcuic and Campeanu (1981) attributed to the Treitz ligament the ability to open the DJJ angle during normal emptying of the duodenal contents into the jejunum. This function was supposed to be carried out by the well - developed smooth muscle bundles of the borders of the Treitz ligament, which were frequently inserted into the DJJ (Meyers, 1995). The afore - mentioned works are not in contradiction with our suggestion that an anatomical sphincter exists at the DJJ since the reported muscle bundles of the Treitz ligament was observed to be in continuation with the outer longitudinal, not the inner circular layer of the duodenum (Costacurta, 1972).

Furthermore, the presence of a high density of neurons at three levels of the DJJ in the present work indicates the specific role of each in supplying a particular structure. The first group, observed in the vicinity of the prominent muscularis mucosa in the present work, may be concerned with supplying the glandular part of the mucosa, its blood vessels, and the well - developed muscularis mucosa. That opinion is in agreement with Fawcett (1994) and Shafik et al. (1999) who reported that this plexus was concerned with controlling local intestinal secretion, a' sorption, and muscle contraction.

The second group of neurons noticed in the submucosa in the current study, already known as Meissner's plexus, may be involved in the control of high vascularity detected in the submucosa (Cormack, 1987; Shafik et al., 1999), the supply of mucosal glands and muscularis mucosa (Coremack, 1987), or in the secretion of neurotransmitters in that part of the alimentary tract (Shafik et al., 1999).

The present work detected the third group of neurons in the vicinity of the markedly thickened inner circular layer of the muscularis externa of the DJJ. That group, known as the Auerbach's plexus, was stated to have both sympathetic and parasympathetic functions (Kessel, 1998). Since it is well known that the muscularis externa is normally supplied by Auerbach's plexus, situated between the circular and the outer longitudinal layers, and is concerned with regulating muscle tone and peristalsis (Cormack, 1987; Fawcett, 1994), the present research proposes that this neuronal arrangement reported in the present work may play a role in supplying the observed highly thickened muscularis externa of the DJJ, thus regulating its function as a sphincter. We suggest that a peristaltic wave from the duodeno - jejunal sphincter is responsible for moving the luminal contents along the jejunum gradually, whereby a wave of contraction moves distally, forcing the luminal content into the relaxed jejunal segment ahead. That suggestion is in agreement with the peristaltic wave description (Stevens and Lowe, 1997). However, electrophysiological studies should be further performed to confirm that suggestion.

In addition to the afore - mentioned explanations, both Meissner's and Auerbach's plexuses were further reported to constitute the intrinsic innervation of small intestine, and contain some sensory nerves that may function as either chemoreceptors mediating the composition of the intestinal contents, or mechanoreceptors mediating visceral reflexes such as hunger and degree of fullness or expansion (Stevens and Lowe, 1997; Junqueira et al., 1998). That intrinsic innervation formed by those two plexuses was stated to be responsible for the intestinal contractions occurring in the event of the total absence of the extrinsic intestinal innervation (Junqueira et al., 1998). Therefore, the abundant autonomic innervation that the small intestine receives, and particularly the DJJ as observed in the present study, provides an anatomic explanation of the widely observed action of emotional stress on the digestive tract as a whole - a phenomenon of importance in psychosomatic medicine (Junqueira et al., 1998).

With regards to the functional significance, food passage occurs as a result of interaction between gastric and intestinal factors providing synchronous movement of chyme from the stomach and duodenum to the distal small intestine via their coordinated contractions (Houghton et al., 1988 - a, b). Unfortunately, the physiologic controlling mechanisms of that process are not completely understood. However, one of the possible mechanisms of pyloroduodenal coordination is synchronous activity of the pyloric sphincter and the DJJ in which a "functional" sphincter was suspected (Read et al., 1980; Saenko et al., 1989 - a; Virchenko et al., 1993), as well

as an "anatomical" sphincter is suggested in the present work. It has also been reported that the disturbance of distal duodenal motility might be a factor leading to pyloroduodenal dyscoordination that would in turn lead to an increase in duodenogastric reflux (Sousa et al., 1988). Therefore, it is possible that in the presence of a positive feedback mechanism between the pylorus and the duodenojejunal sphincter proposed by the present work, synchronous activity of the stomach and duodenum is achieved. Moreover, we suggest that a high absorption rate would result from prolongation of chyme contact time with the absorptive surface due to delayed emptying of the duodenum by the duodenojejunal sphincter proposed by the present work. That, in turn, regulates the processes of alimentation and absorption, and hence prevents duodenogastric reflux. Dysfunction of this regulatory mechanism may prove to be a factor in the pathogenesis of idiopathic duodenal obstruction (Akin et al., 1976; Major et al., 1960). That suggestion is based on the work of Saenko et al. (1989 - a) that reported a decrease in the degree of gastric and duodenal emptying when exclusion of the duodenum (Jejunal delivery) was performed via duodenojejunostomy.

In view of the findings of the present work, we suggest that a sphincter, both physiologically and anatomically, exists at the DJJ. We believe that this sphincter provides more coordinated activity of the stomach and duodenum, therefore serving as one of the factors regulating the process of digestion and absorption of nutrients from the duodenum.

SUMMARY

The possible existence of an "anatomical" sphincter at the duodeno - jejunal junction (DJJ) has scarcely been addressed in the literature. However, studies have demonstrated that the DJJ was probably a "functional" sphincter that provided coordinated activity of the stomach and the duodenum.

The present study used thirty adult albino rats of Sprague - Dawley strain to investigate the histological structure of the DJJ using Haematoxylin and Eosin, Masson's trichrome, and silver stains. The DJJ was identified by the absence, following a gradual decrease, of the Brunner's glands in the submucosa.

The mucosal folding was noticed to increase at the DJJ, together with a prominent muscularis mucosa. Moreover, both the submucosa and the muscularis externa were observed to be highly vascular. Furthermore, high content of collagenous fibers was observed in the submucosa.

The main finding was the marked thickening of the circular muscle coat towards the jejunum. Furthermore, a marked increase in the nerve supply was noticed at three levels of the DJJ : in the vicinity of the muscularis mucosa, in the middle of the submucosa, and near the circular layer of the muscularis externa where the nerve cells were arranged in rows.

The results of the current study suggest the presence of an anatomical sphincter at the DJJ that seems to regulate duodenal emptying into the jejunum, thus creating optimal conditions for duodenal alimentation of ingested food.

REFERENCES

1. **Akin, J.T.; Gray, S.W. and Skandalakis, J.E. (1976)** : Vascular compression of the duodenum, presentation of ten cases and review of literature. *Surgery*, **79** : 515 - 522.
2. **Chuo, C.C. (1982)** : Relationship between intestinal blood flow and motility. *Annu. Rev. Physiol.*, **44** : 29 - 34.
3. **Cormack, D.H. (1987)** : Ham's histology. 9th ed., J.B. Lippencott Company, Philadelphia, London, Mexico City, New York, St. Louis, Sao Paulo, Sydney, 492 - 517.
4. **Costacurta, L. (1972)** : Anatomical and functional aspects of the human suspensory muscle of the duodenum. *Acta Anat.*, **82** : 34 - 46.
5. **Drury, R. and Wallington, E. (1980)** : Carleton's histological technique, 5th ed., Oxford University Press, London, 307.
6. **Fawcett, D.W. (1994)** : Intestine in Textbook of Histology. 12th ed., Bloom, W. and Fawcett, D.W. (eds.), Chapman and Hill, New York, 637 - 642.
7. **Houghton, L.A.; Read, N.W. and Heddle, R. (1988 - a)** : Motor activity of the gastric antrum, pylorus, and duodenum under fasted conditions and after a liquid meal. *Gastroenterol.*, **94** : 1276 - 1284.
8. **Houghton, L.A.; Read, N.W. and Heddle, R. (1988 - b)** : Relationship of the motor activity of the antrum, pylorus, and duodenum to gastric emptying of a solid - liquid mixed meal. *Gastroenterol.*, **94** : 1285 - 1291.
9. **Junqueira, L.C.; Carneiro, J. and Kelley, R.O. (1998)** : Basic Histology. 9th ed., Middle East ed., Appelton and Lange, Norwalk, Connecticut, San Mateo, California, 272 - 303.
10. **Kerlin, P.; Zinsmlister, A. and Philips, S. (1982)** : Relationship of motility to flow of contents in the human small intestine. *Gastroenterol.*, **82** : 701 - 706.

11. **Kessel, R.G. (1998)** : Basic medical histology : The biology of cells, tissues, and organs. Oxford University Press, Oxford, New York, 372 - 396.
12. **Kiernan, J.A. (1999)** : Histological and histochemical methods : Theory and practice. 3rd ed., Butterworth - Heinemann, Oxford, Auckland, Boston, Johannesburg, Melbourne, New Delhi, 370.
13. **Major, J.W.; Ottenheimer, E.J. and Whalen, W.A. (1960)** : Duodenal obstruction of the ligament of Treitz. *New Engl. J. Med.*, **262** : 443 - 445.
14. **Masson's, P. (1929)** : Some Histological Methods : Trichrome stainings and their preliminary technique. *Bull. Int. Assoc. Med.*, **12** : 75.
15. **Meyers, M.A. (1995)** : Treiz redux : the ligament of Treitz revisited. *Abdom. Imaging*, **20** : 421 - 424.
16. **Suigley, E.M.M. (1987)** : Small intestinal motor activity - its role in gut homeostasis and disease. *Q. J. Med.*, **65** : 799 - 810.
17. **Read, N.W.; Miles, C.A. and Fisher, D. (1980)** : Transit of a meal through the stomach, small intestine, and colon in normal subjects and its role in pathogenesis of diarrhea. *Gastroenterol.*, **79** : 1276 - 1282.
18. **Repcuic, E. and Campeanu, R. (1981)** : The suspensory muscle of the duodenum. *Morphol. Embryol. (Bucur)*, **27** : 123 - 126.
19. **Saenko, V.F.; Markulan, L.Iu; Belianskii, L.S.; Virchenko, S.B. and Kucherenko, T.L. (1989 - a)** : The role of the duodenojejunal flexure in regulating the motor evacuatory function of the duodenum. *Klin. Khir.*, **2** : 24 - 27.
20. **Saenko, V.F.; Virchenko, S.B.; Kucherenko, T.L. and Belianskii, L.S. (1989 - b)** : The role of Treitz ligament in regulating the evacuation of solid food from the duodenum. *Biull. Eksp. Biol. Med.*, **189** : 263 - 266.
21. **Saenko, V.F.; Virchenko, S.B.; Kucherenko, T.L.; Ettinger, A.P.; Belianskii, L.S. and Markulan, L.Iu. (1990 - a)** : The role of the duodenojejunal junction in regulating the evacuatory function of the duodenum. *Fiziol. Zh.*, **36** : 56 - 63.
22. **Saenko, V.F.; Virchenko, S.B.; Kucherenko, T.L.; Tsedik, N.N. and Ettinger, A.P. (1990 - b)** : Electric activity of the proximal part of the digestive tract in the normal state and after pyloroplasty and transection of the ligament of Treitz in dogs. *Klin. Khir.*, **8** : 21 - 23.
23. **Shafik, A.; Doss, S. and Ali, Y.A. (1999)** : Rectosigmoid junction : anatomical, histological, and radiological studies with special reference to sphincteric function. *Int. J. Colorectal Dis.*, **14** : 237 - 244.

- 24. Sousa, J.E.S.; Troncon, L.E.A. and Andrad, J.I. (1988) :** Comparison between Henley jejunal interposition and Rou-en-Y anastomosis as concerns entero-gastric biliary reflux levels. *Ann. Surg.*, **208** : 597 - 600.
- 25. Stevens, A. and Lowe, J.S. (1997) :** *Human Histology*. 2nd ed.. Mosby, London, Baltimore, Barcelona, Bogotá, Boston, Buenos Aires, Carlsbad, CA, Chicago, Madrid, Mexico City, Milan, Naples, FL, New York, Philadelphia, St. Louis, Seoul, Singapore, Sydney, Taipei, Tokyo, Toronto, Wiesbaden. 194 - 206.
- 26. Virchenko, S.B.; Saenko, V.F.; Kucherenko, T.L.; Tsedik, N.N.; Elbrond, H.; Djurhuus, J.C. and Funch - Jensen, P. (1993) :** The duodenojejunal junction and Treitz ligament in the regulation of duodenal emptying. *Scand. J. Gastroenterol.*, **28** : 753 - 759.
- 27. Zypen, F. van der and Reves, E. (1984) :** Investigation of development, structure and function of the phrenicocolic and duodenal suspensory ligaments. *Acta Anat.*, **119** : 142 - 148.

الوصلة بين الاثنى عشر والصائم : هل هي صمام تشريحي ؟

جورج فايق برسوم حنا - هببر ابراهيم ايسخرون - رنا علي البشبيشي

قسم التشريح - كلية الطب - جامعة عين شمس

نادرا ما تم تناول احتمال وجود صمام تشريحي في الوصلة بين الاثنى عشر والصائم في الأبحاث . وبالرغم من ذلك ، فقد أوضحت الدراسات أنه يوجد صمام وظيفي في هذه الوصلة موفرا نشاطا متسقا ما بين المعدة والاثنى عشر .

استخدمت الدراسة الحالية ثلاثين فأرا بالغاً أبيض من فصيلة سبراج - داوولي لفحص التركيب النسيجي للوصلة بين الاثنى عشر والصائم باستخدام صبغات الهيماتوكسيلين والايوسين ، ميسون ثلاثية اللون ، والفضة . وقد تم التعرف على الوصلة بين الاثنى عشر والصائم باختفاء غدد برونر في الطبقة تحت الطلائية بعد نقصانها تدريجياً .

وقد لوحظ ازدياد في ثنايا السطح المخاطي مع بروز واضح في الطبقة العضلية المخاطية . وعلاوة على ذلك ، فقد كانت كل من الطبقة تحت الطلائية والطبقة العضلية الخارجية وعائية بدرجة عالية . وبالإضافة الى ذلك ، فقد لوحظت زيادة في كمية الأنسجة الليفية في الطبقة تحت الطلائية .

ان النتيجة الأساسية التي تم التوصل اليها تتمثل في الزيادة الواضحة في سمك الغطاء العضلي الدائري باتجاه الصائم . وبالإضافة الى ذلك ، فقد لوحظت زيادة كبيرة في التغذية العصبية في ثلاثة أماكن في الوصلة بين الاثنى عشر والصائم : في المنطقة المجاورة للطبقة العضلية المخاطية ، وفي منتصف الطبقة تحت الطلائية ،

بالقرب من الغطاء الدائرى للطبقة العضلية الخارجية حيث اصطلفت الخلايا العصبية
فى صفوف .

ان نتائج هذا البحث تقترح وجود صمام تشريحي فى الوصلة بين الاثنى عشر
والصائم الذى يبدو أنه ينظم تفريغ الاثنى عشر فى الصائم مهيتا بذلك أفضل الظروف
للتمثيل الغذائى فى الاثنى عشر .

مجلة التشريح المصرية، ٢٦، (٢)، يوليو ٢٠٠٣